

# Clinical Examination of SPINE

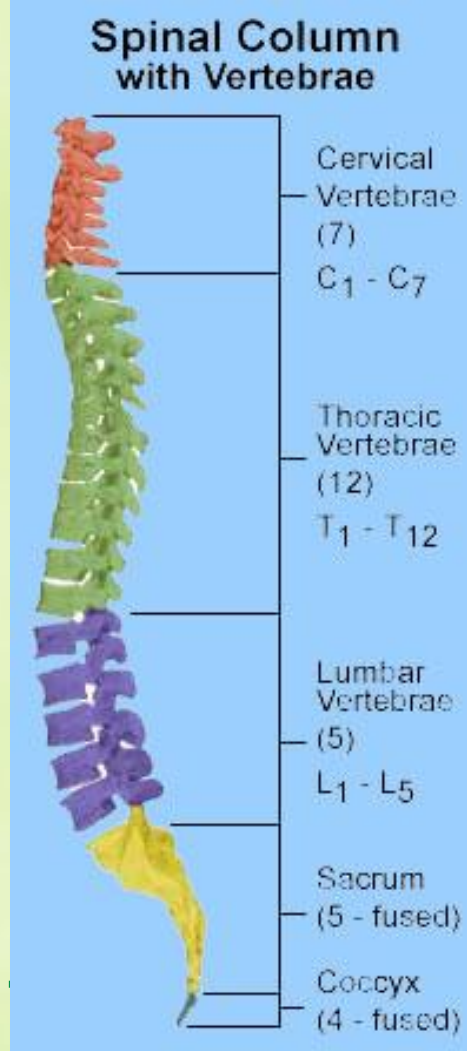
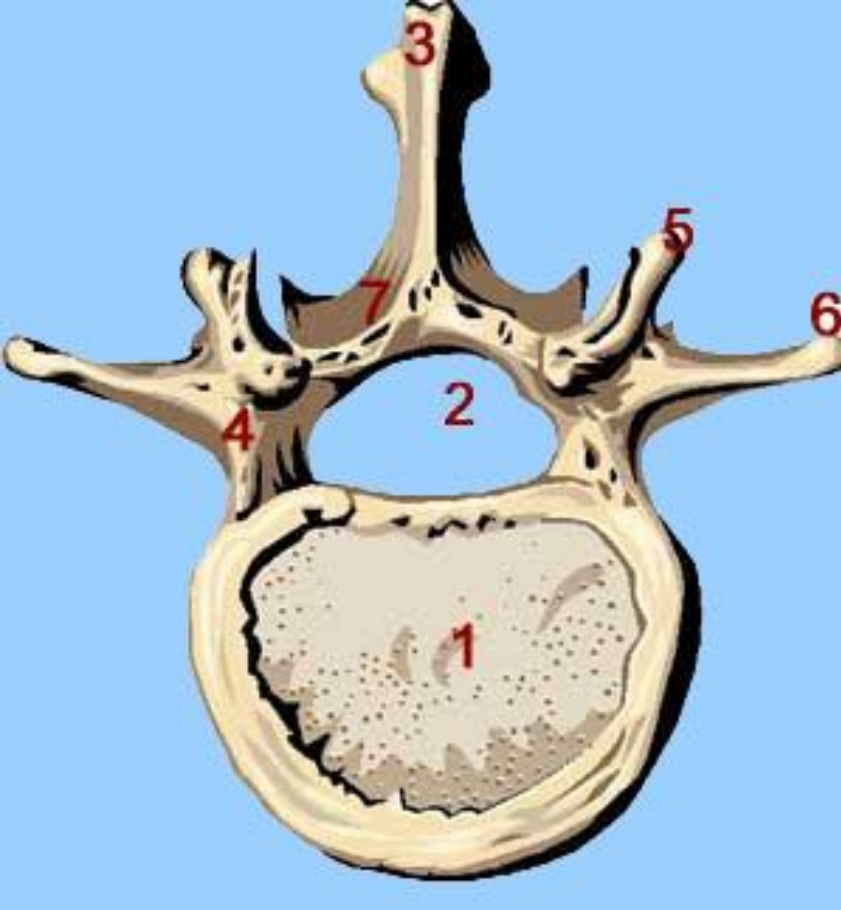
**Rajagopalan**  
**Professor, Dept. of Orthopedics**  
**St. John's Medical College**  
**Bangalore**

Bone School @ Bangalore

Pearson International Edition

Physical  
Examination  
of the Spine  
& Extremities

Stanley Hoppenfeld



Vital to the examination of spine is to have a good knowledge of the anatomy of this area.

# Clinical examination of spine

- History
- Inspection
- Palpation
- Movement and measurement
- Neurology of the limbs

# Before starting

- Introduce yourself
- Ask permission to perform examination
- Explain what the examination entails
- Expose the patient appropriately - the patient should undress to their undergarments including the lower limbs.
- Tell the patient to let you know if anything you do is uncomfortable
- Remember - always watch the patients face

# History

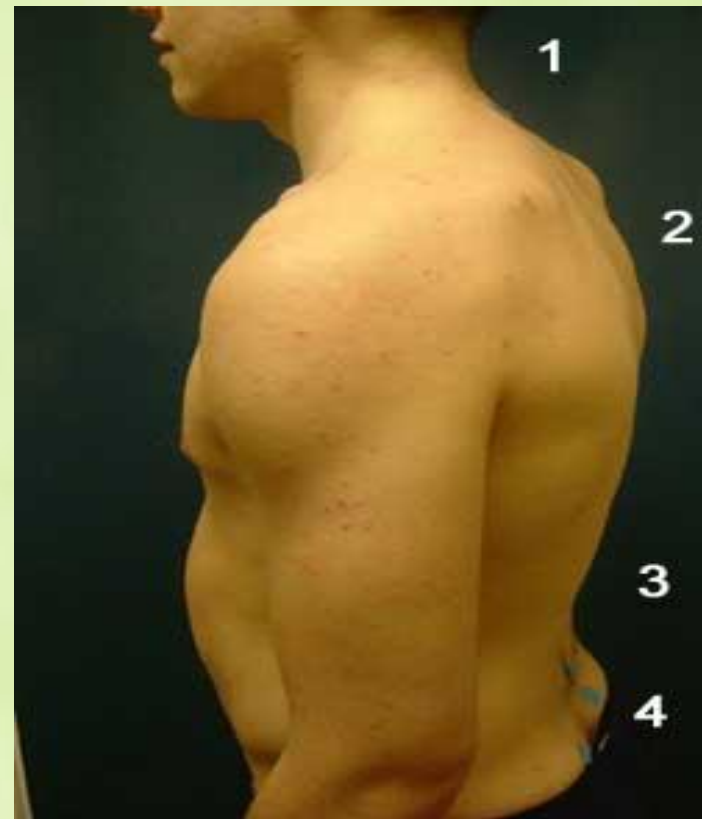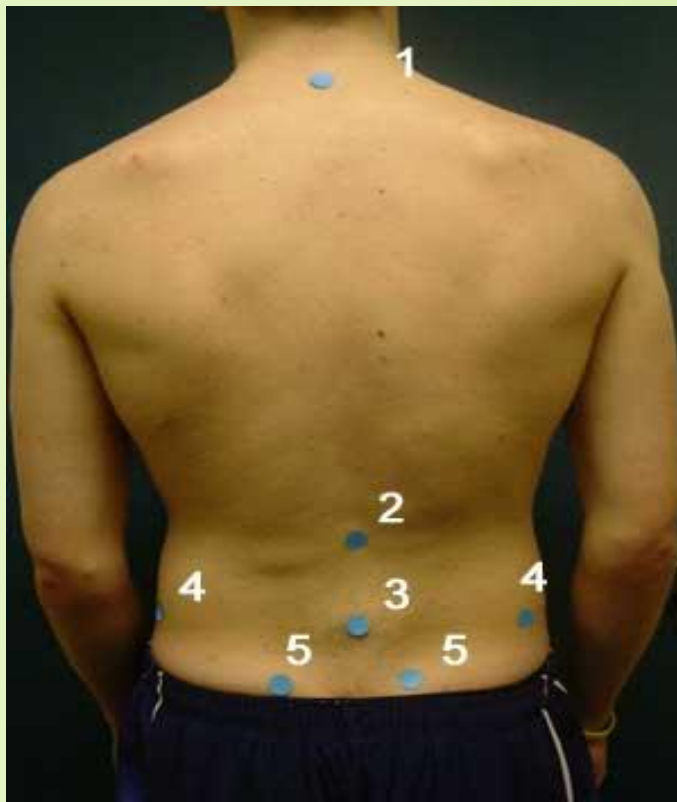
- Injury : type, violence, mechanism (direct, indirect, rotational) site.
- Pain: onset, nature, site, radiation,
- Deformity
- ADL
- Bladder / bowel function
- Treatment

# Inspection

- Suitably undressed, usually down to underwear.
- Start with the patient standing, then lying prone and finally lying supine.
- General observation
  - Does the patient look well?
  - Assess the patient's posture - any obvious conditions?

# Patient Standing

- Remember to inspect from all sides (front, laterally and from behind):



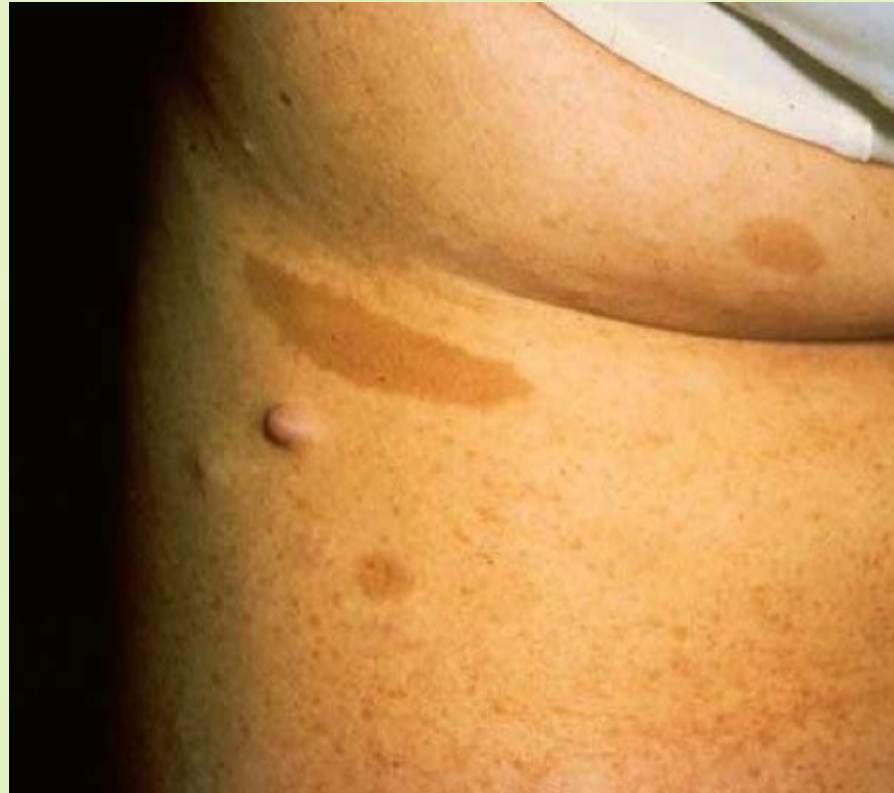# Inspection

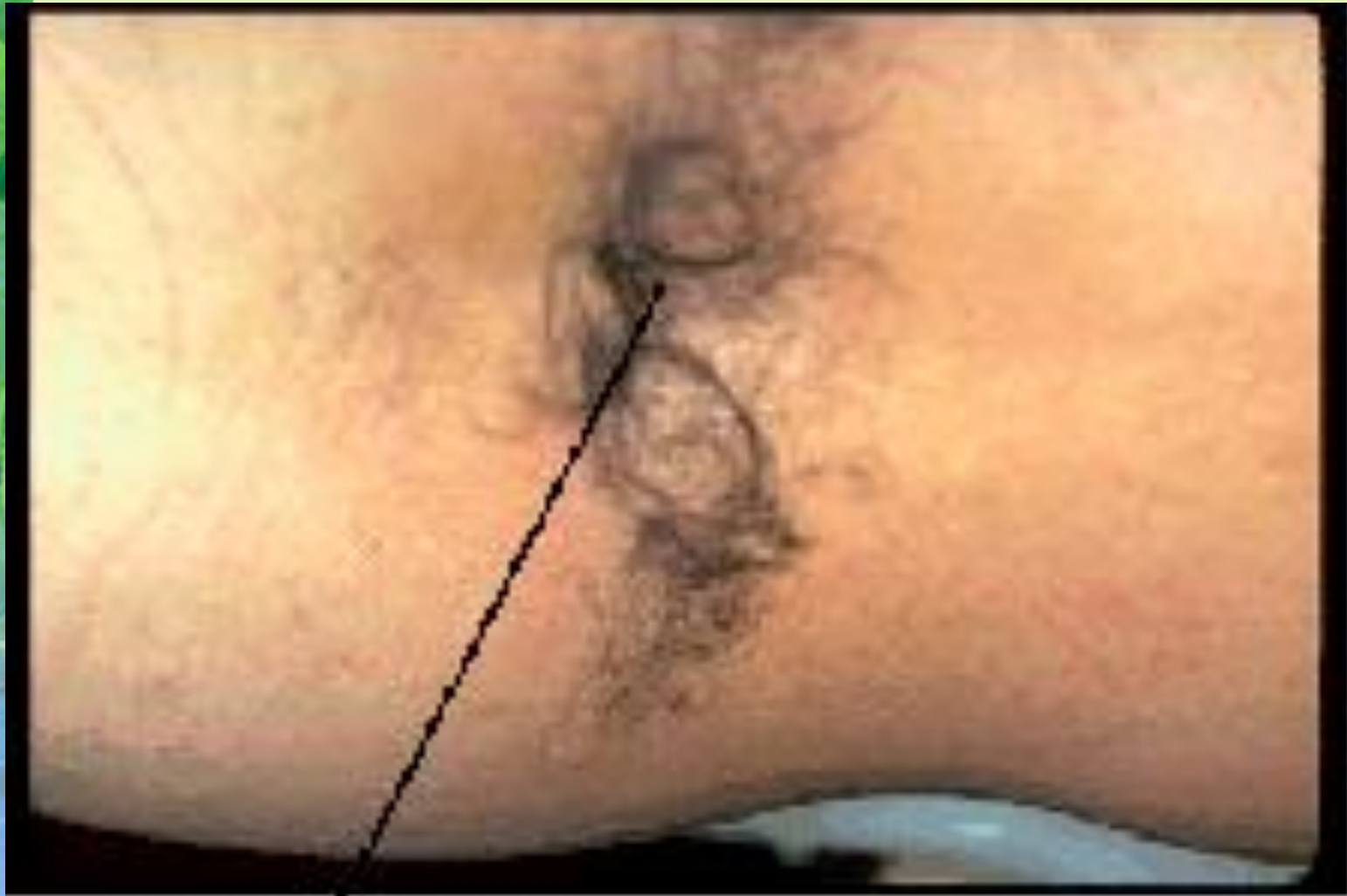1. Attitude and deformity
2. Position of head, shoulder, scapula
3. Rib hump
4. swellings, sinus, skin
5. Gait



- Skin
  - Scars (surgical scars)
  - Sinuses (deep infection)
  - Unusual skin creases
  - Pigmentation
    - Cafe au lait spots (Neurofibromatosis)
    - Hairy patch (spinal dysraphism)
    - Mongolian Blue spot (no clinical significance - more common in asians)

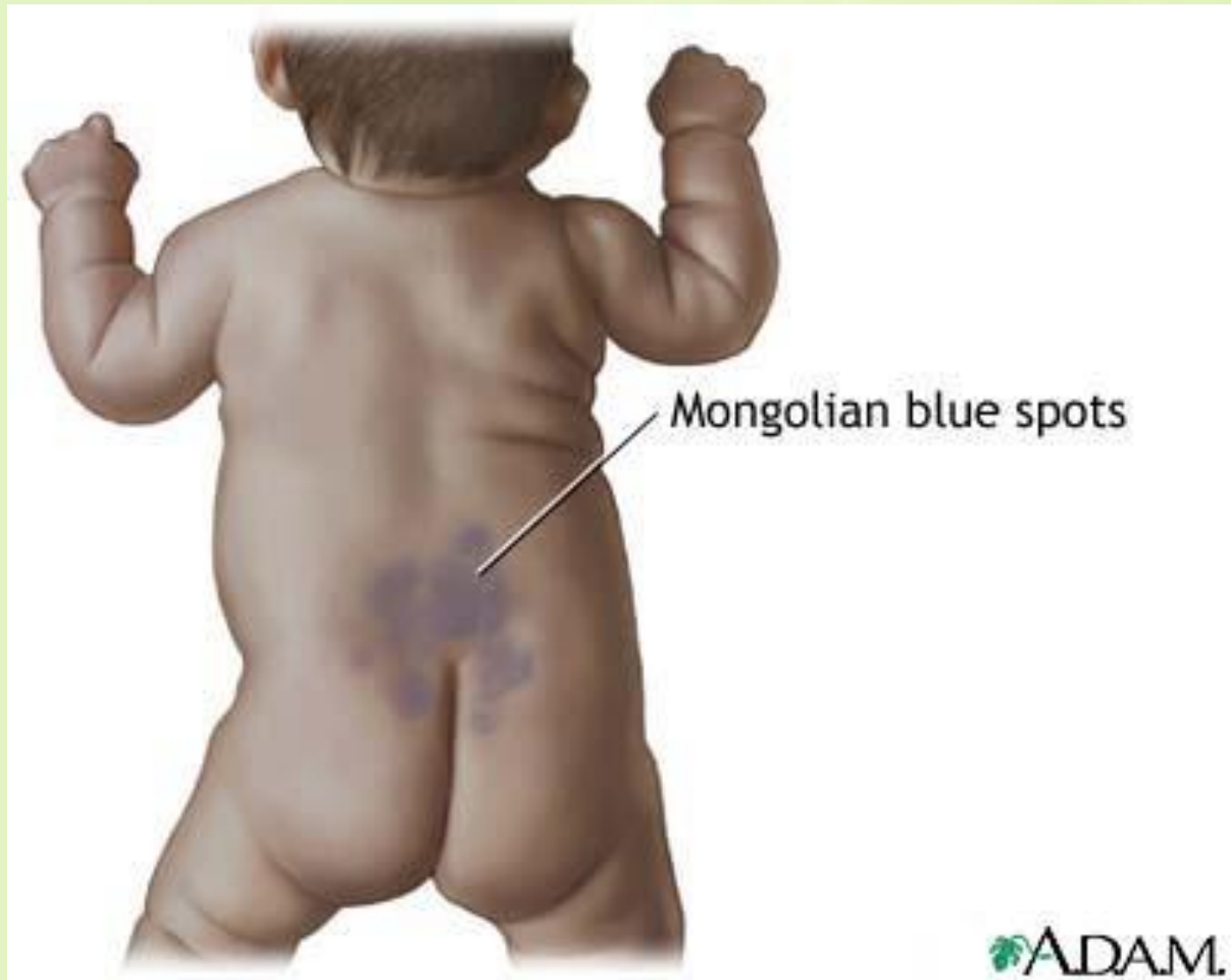# Cafe au lait spots Neurofibromatosis





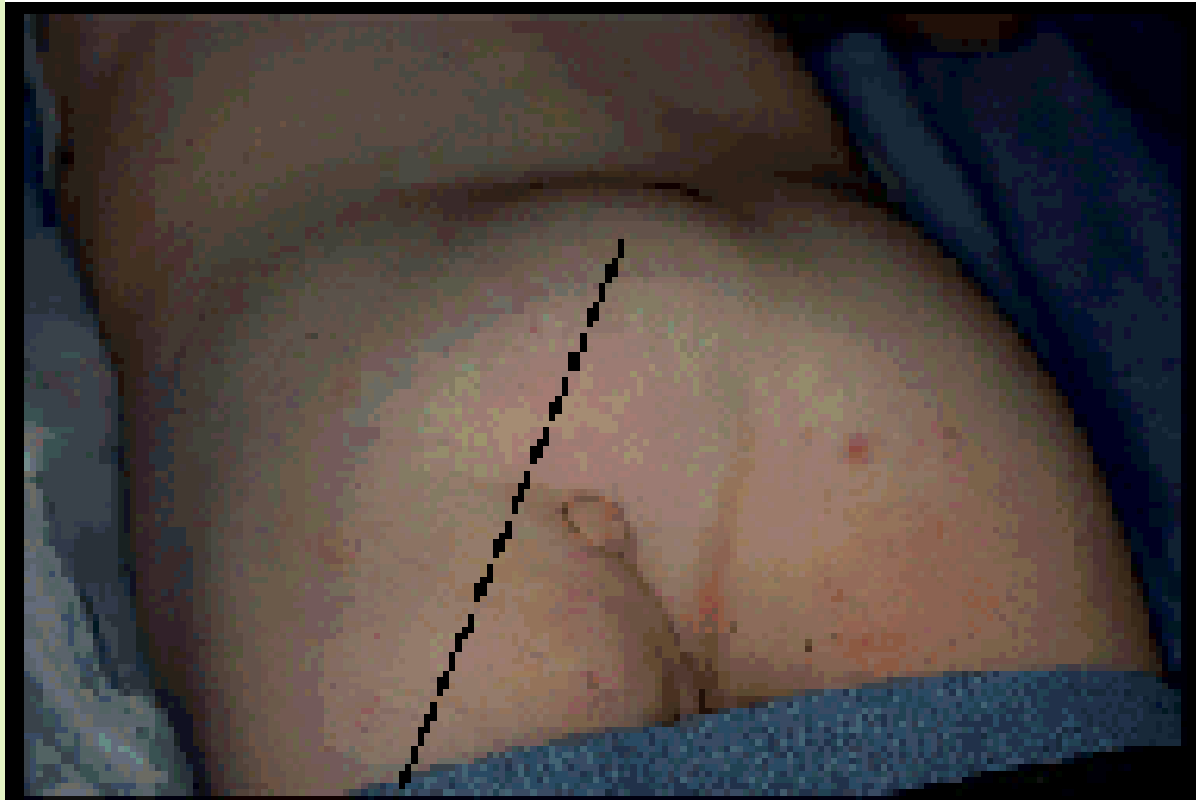
**Hairy Patch**

Bone School @ Bangalore



Mongolian Blue spot (no clinical significance - more common in asians)

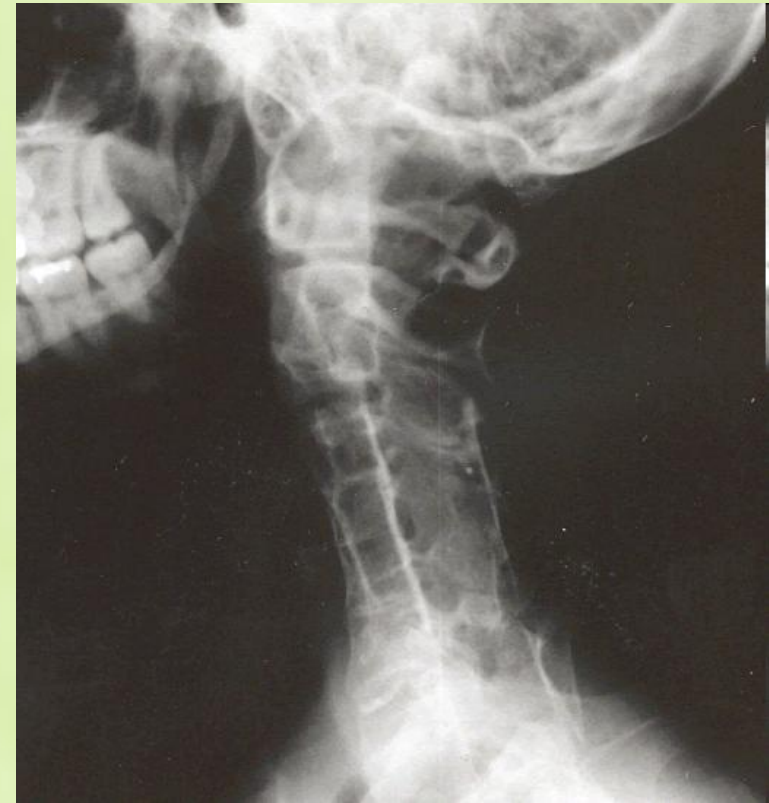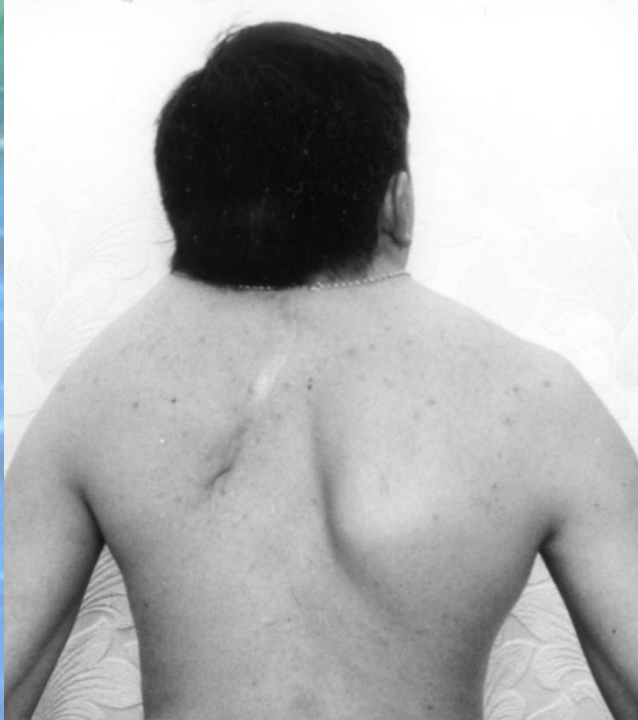- **Lumps: abscess, tumour (e.g. sacral lipoma), prominent paravertebral muscle spasm**



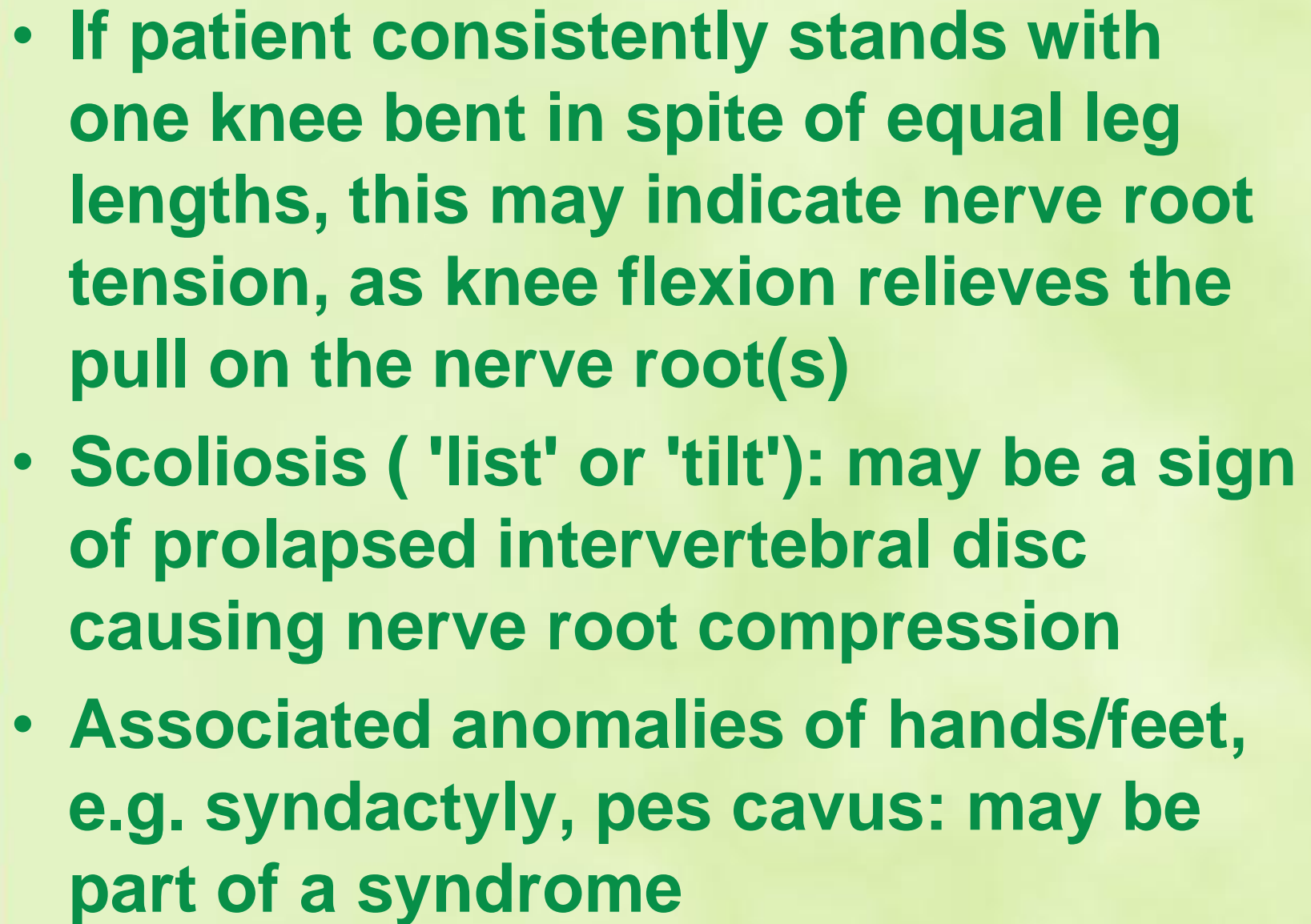
**Lipoma**

# Klippel-Feil syndrome

- Low hairline due to short neck:
- Klippel-Feil syndrome:
- fusion or absence of cervical vertebrae;
- may be associated with Sprengel shoulder (undescended scapula)



- Down / Morquio syndromes: Atlanto-axial instability
- Asymmetry of shoulder height / trunk balance / loin crease:
- scoliosis
- Leg length discrepancy (check level of iliac crests)

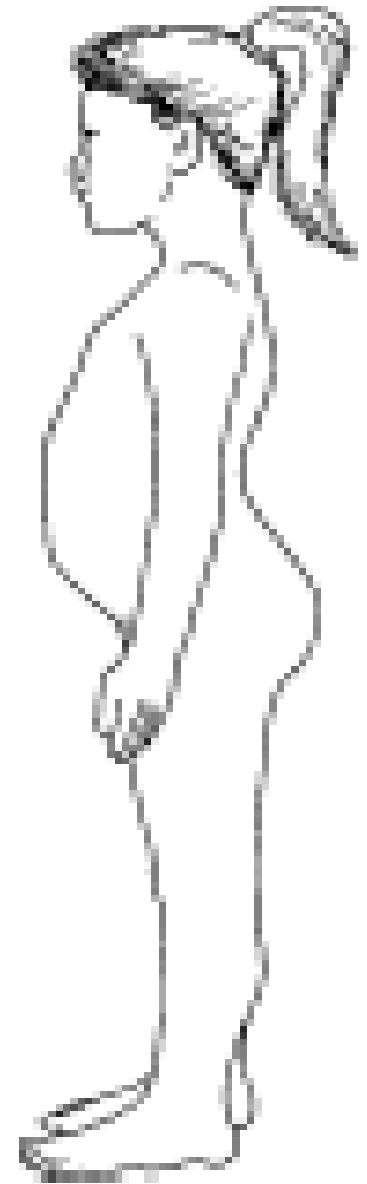- 
- **If patient consistently stands with one knee bent in spite of equal leg lengths, this may indicate nerve root tension, as knee flexion relieves the pull on the nerve root(s)**
  - **Scoliosis ( 'list' or 'tilt'):** may be a sign of prolapsed intervertebral disc causing nerve root compression
  - **Associated anomalies of hands/feet, e.g. syndactyly, pes cavus:** may be part of a syndrome



- Spine
  - Kyphosis (exaggerated or reduced)
  - Lumbar lordosis (exaggerated or reduced)
  - Scoliosis (asymmetry of shoulder height / trunk balance / loin crease)
- Round backing / hunched shoulders: Schuermann's disease/kyphosis
- Gibbus :
- Any chest deformity

## wall test

- The wall test will unmask even small fixed flexion deformities:
- Ask the patient to stand with the back straight against a wall.
- Observe whether the following are in contact with the wall:
  - Occiput
  - Shoulders
  - Buttocks
  - Heels



## *Patient Walking*

- Observe the gait

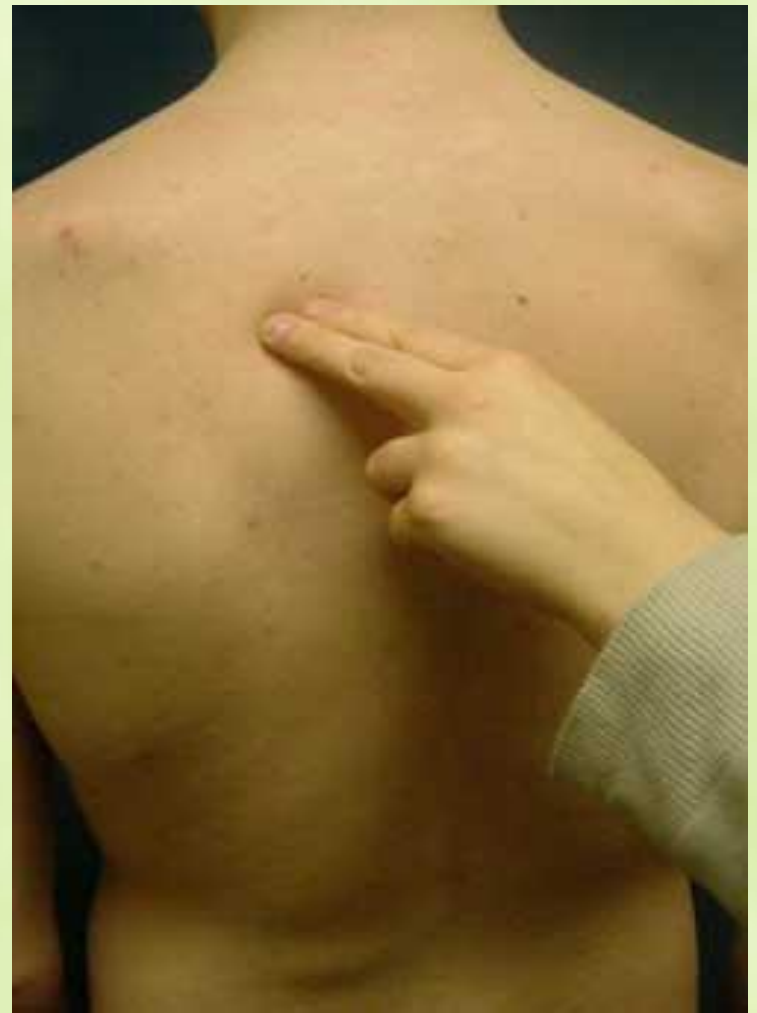
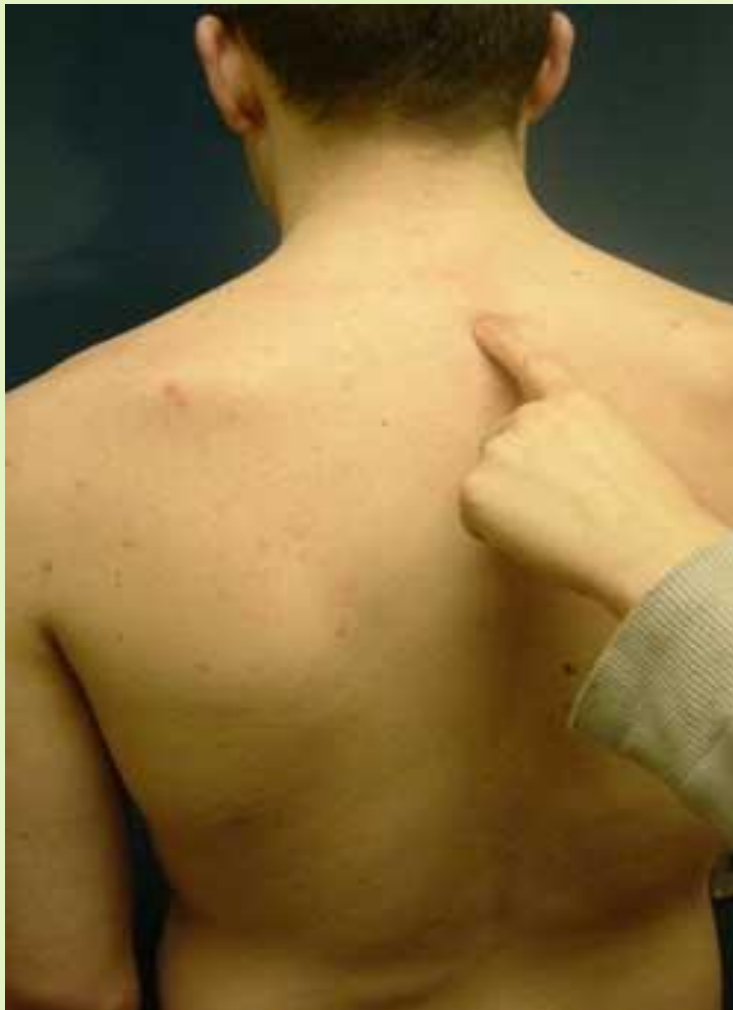
# Gait


- Have the patient walk normally then on their toes (tests S1) then on their heels (tests L4/5).
- Observe for abnormal gait patterns including
  - Antalgic
  - Trendelenburg
  - Short leg
  - Foot drop

# Palpation

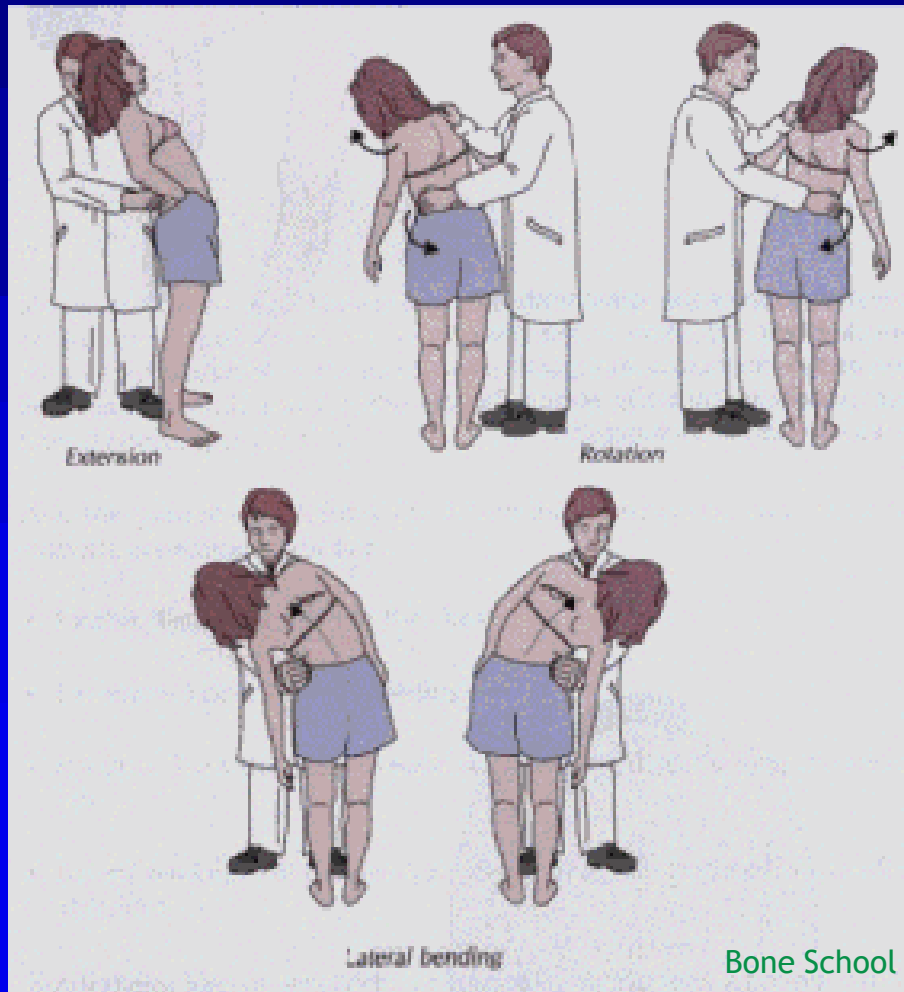
- You have to know your anatomy to know what you are feeling!
- With the patient standing and then perhaps later, lying supine, palpate the back for the:
  - skin temperature
  - deformity of the spine - steps or a steady contour?



vertebral tenderness - localised or general ?  
paraspinal spasm and muscle tenderness  
sacro-iliac tenderness in sacroilitis

- 
- Elsewhere:
  - feel for peripheral pulses
  - palpate groin and abdomen for abscesses
  - Chest, abdominal, rectal examination

# Spine Exam



- Range of Motion and Maneuvers
  - Neck: flexion & extension (skull & C1), rotation (C1-C2), lateral bending (C2-C7)
  - Spine: flexion, extension, rotation, lateral bending



# Movts and measurements

- Measurement of mobility of the spine
- Movements
- Chest expansion
- costovertebral movements are gauged by asking the patient to breathe in and out: the distance between maximal inspiration and expiration is normally 5cm.

# Measurement of mobility of the spine

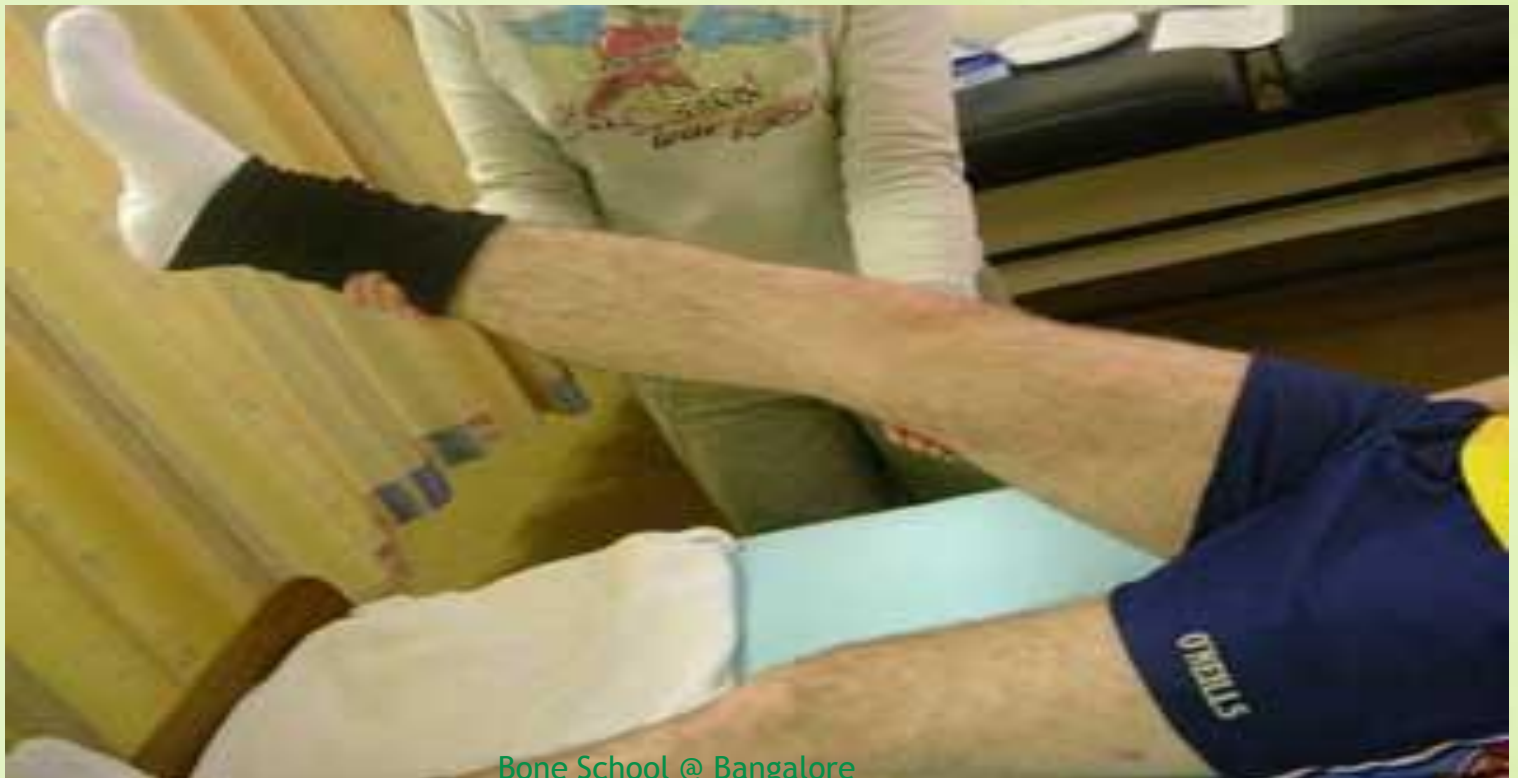- Mark 2 points, one in T1 and another in L1. ask the patient to bend to the extent possible. Normally there is an increase by 8 cm.
- Mark 2 points, one in L1 and another in S1. ask the patient to bend to the extent possible. Normally there is an increase by 8 to 10 cm.

# Neurological examination

- the patient is then asked to lie supine and the straight leg raise test is performed.
- carry out neurological testing of power;
- sensation -
- reflexes -
- do a rectal examination - check tone, power, sensation

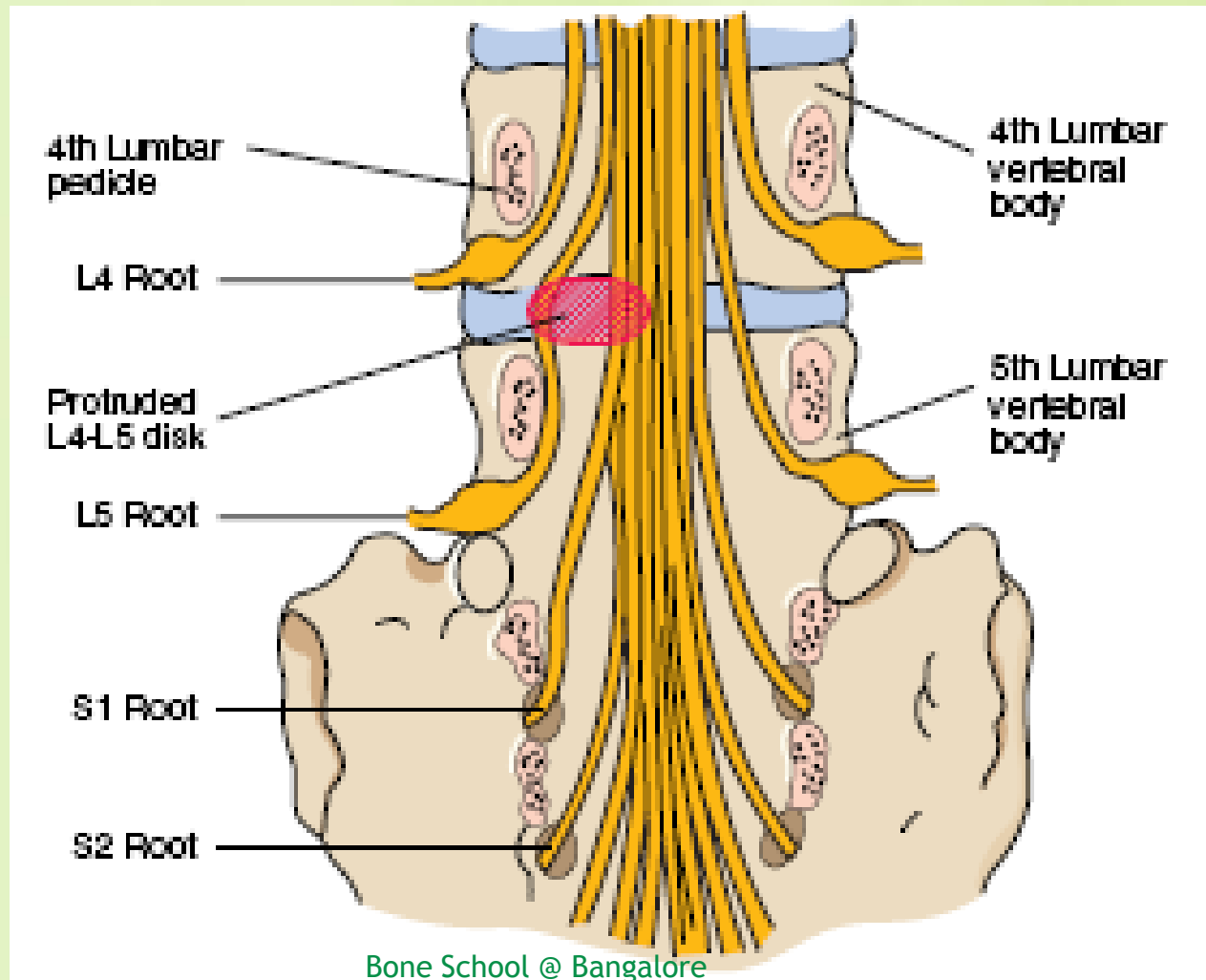
# Straight Leg Raising Test (SLR)

- This is a test for lumbosacral nerve root irritation for example, due to disc prolapse.

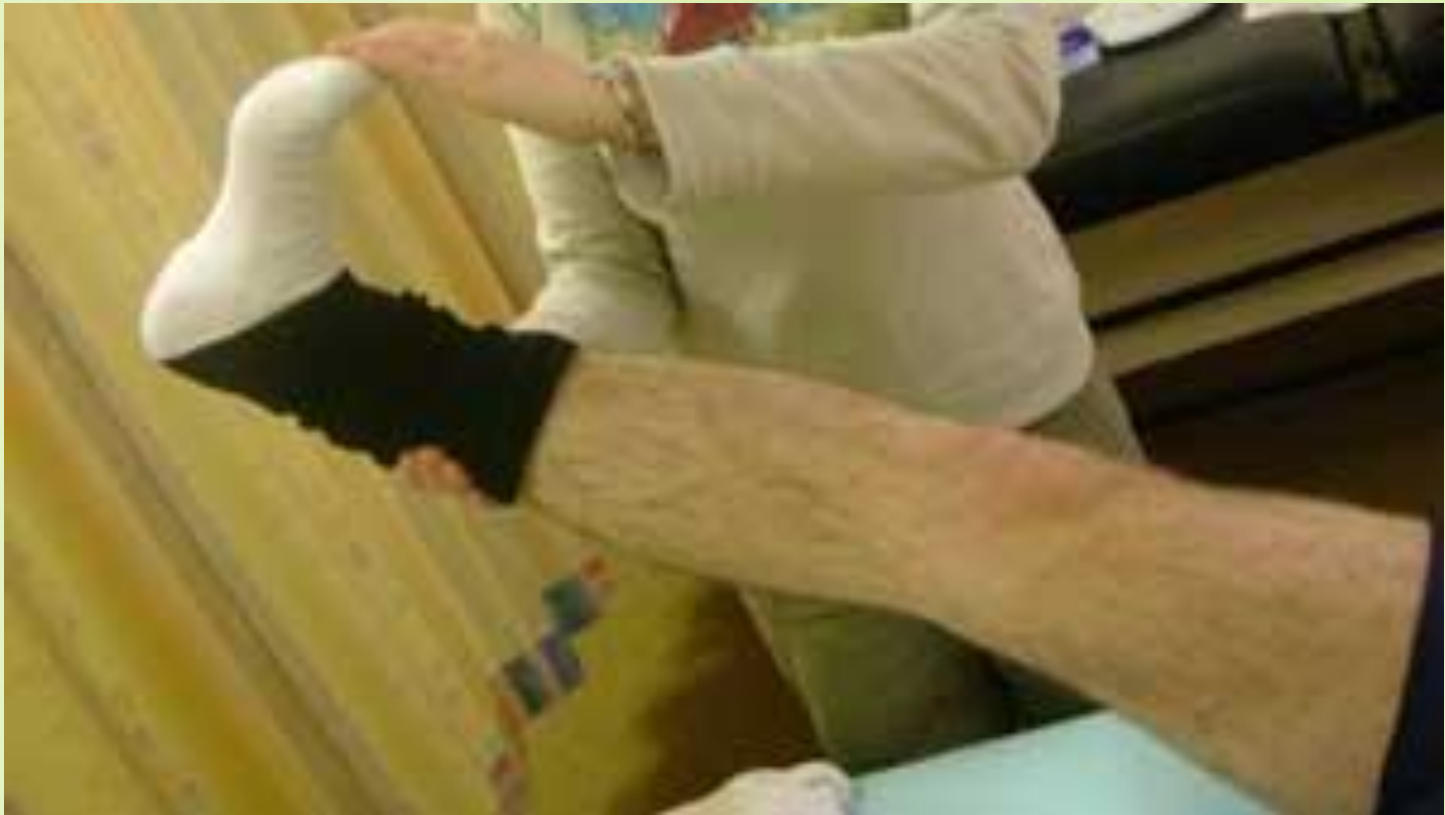

- With the patient laid on their back:
- raise one leg - knee absolutely straight - until pain is experienced in the thigh, buttock and calf.
- record angle at which pain occurs - a normal value would be 80-90 degrees - higher in people with ligament laxity
- perform sciatic stretch test - dorsiflex foot at this point of discomfort - test is positive if additional pain results.

- A typical positive SLR is one that reproduces the patient's sciatica between 30 and 60 degrees.



- When the limit of SLR is reached, dorsiflexion of the ankle produces acute accentuation of pain.



- straight leg raising, by itself, can produce pain from a variety of sources, including myogenic pain, ischial bursitis, annular tear, and hamstring tightness, as well as herniated disc
- Pain upon straight leg raising before the leg is raised 30 degrees cannot be due to disc prolapse as the nerve root is not stretched within this range.
- Another explanation of nerve root irritation must then be sought.



# Bowstring Sign

- sciatic stretch test
- performed after a straight leg raising test by lowering the affecting leg a few degrees below the point
- popliteal compression:
- applying compression to the popliteal fossa tensions the sciatic nerve and should provoke symptoms with a lesser degree of a SLR (removing hamstring irritation as a cause of symptoms)

# Crossed SLR

- Crossed SLR - Severe root irritation is indicated when straight raising of the leg on the unaffected side produces pain on the affected side.
- SLR is sensitive, but unspecific, whereas crossed SLR is very specific, but its sensitivity is low (Hakelius & Hindmarsh 1972, Spangfort 1972).

- Straight leg raising has a sensitivity of 91% its specificity is only 32%
- it is useful in “ruling out” disc herniation when it is absent.
- If present, crossed straight leg raising is specific (98%, but is not very sensitive (32%)
- Therefore, it is useful to confirm (“rule in”) disc herniation, but its absence is not meaningful.

# Maneuvers

- Seated SLR
  - Seat patient at edge of bed (leg 90 degrees flexed)
  - Extend leg at knee without raising leg off table
  - If patient arches back with both arms extended and has pain below knee, this indicates sciatic involvement
  - Examiner can correlate results of both supine and seated SLR (they should correlate if patient has real nerve root involvement)

# How to assess for malingering - Reverse sciatic tension test

- performed by plantar flexing rather than dorsiflexing the foot
- if this results in increased complaints of pain, then pt is malingerer

# How to assess for Malingering

- Hoover test (assesses true leg weakness)
  - Patient lies supine
  - Examiner cups hands under heels of patient
  - Ask patient to raise the weak leg off table
  - If no downward pressure is felt from unaffected leg as patient lifts affected leg, then patient is not giving a full effort

# How to assess for Malingering

- Waddell's Signs
  - Superficial, non-anatomic tenderness (pinching or stroking skin replicates back pain)
  - Axial loading (pressure on top of head) replicates low back pain
  - Distraction – difference between SLR and seated SLR
  - Non-physiologic pain patterns (doesn't follow nerve roots)
  - Voluntary release during strength testing

# Maneuvers

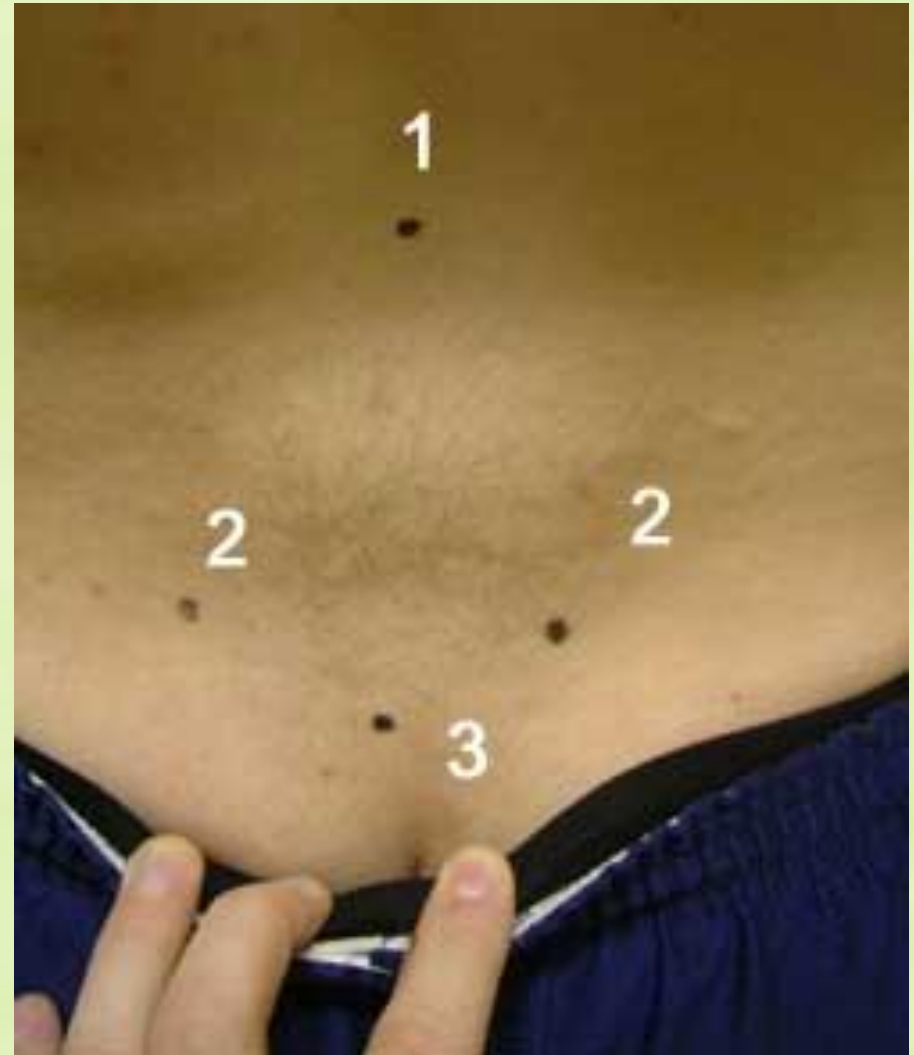
- FAIR position (for Piriformis Syndrome)
  - Place patient on side
  - Flex, Adduct, Internally Rotate affected leg
  - This position stretches the piriformis muscle maximally which would irritate sciatic nerve if patient has piriformis syndrome



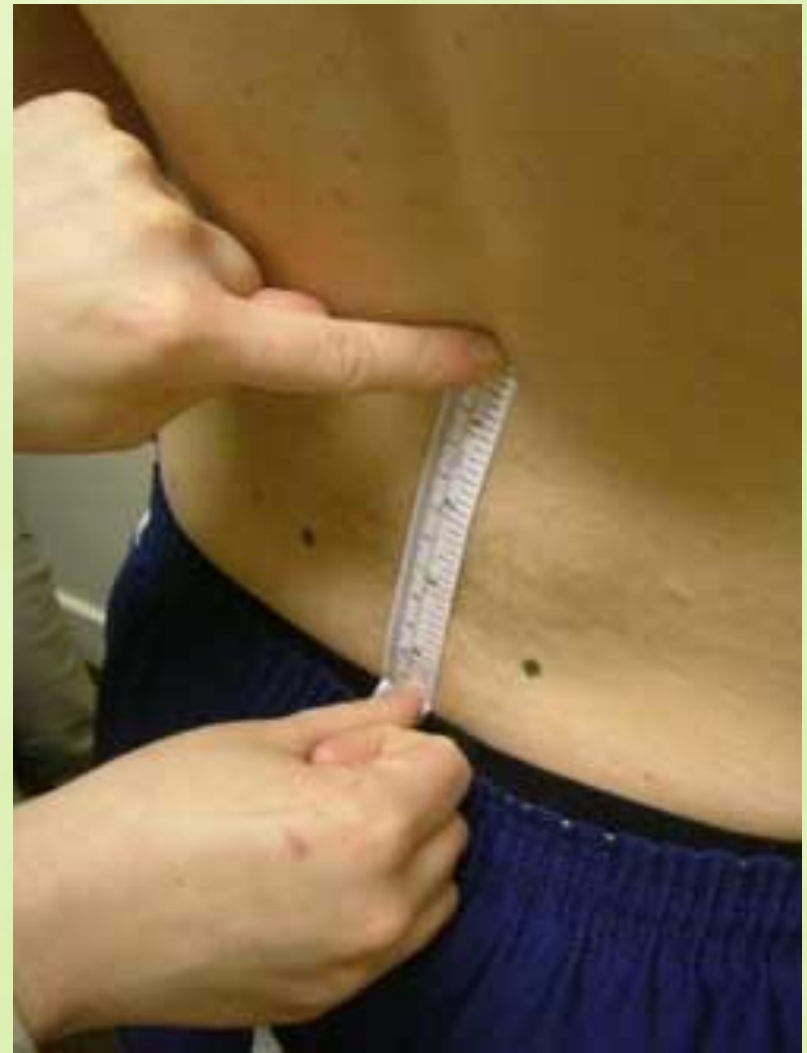# Schober's test

- Schober's test assesses the amount of lumbar flexion.
- In lumbar spine flexion, hip flexion can compensate to a considerable extent for a loss of spinal flexion.
- Schober's test done to objectively measure the degree of spinal flexion.

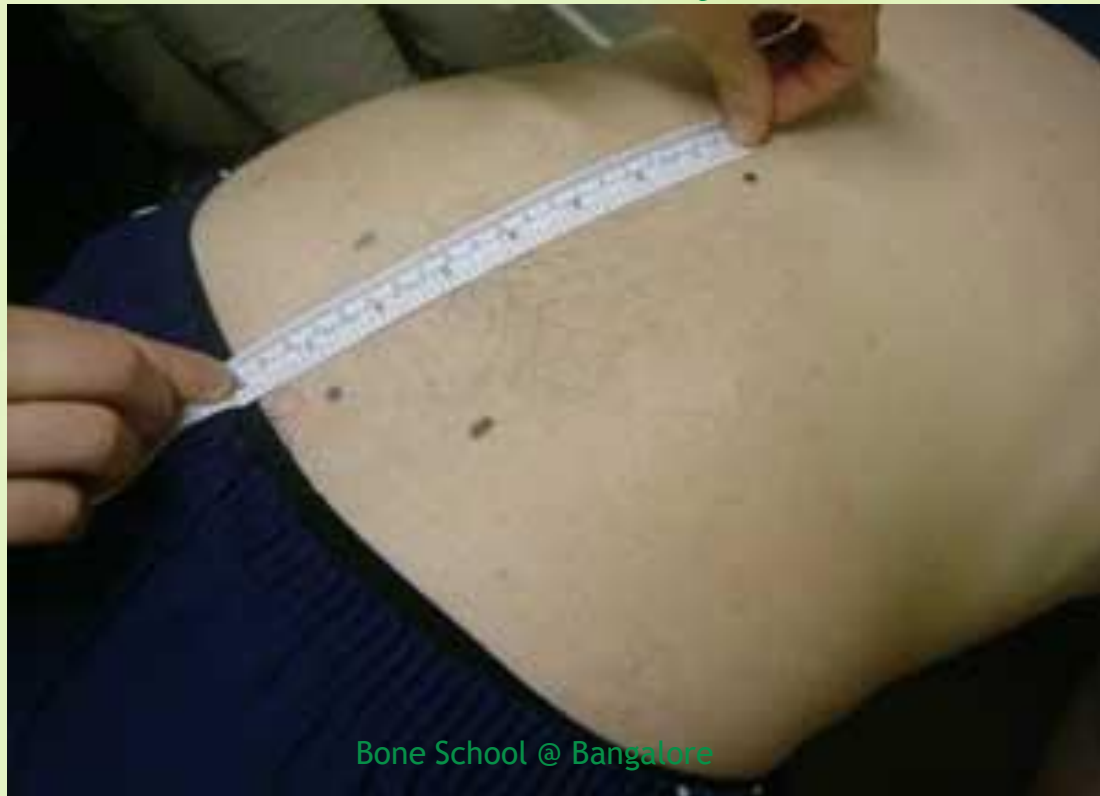- Firstly identify the Dimples of Venus.
- Now in the midline, use a tape measure and pen to mark a point 10cm superior to, and an other mark 5 cm inferior to this point.



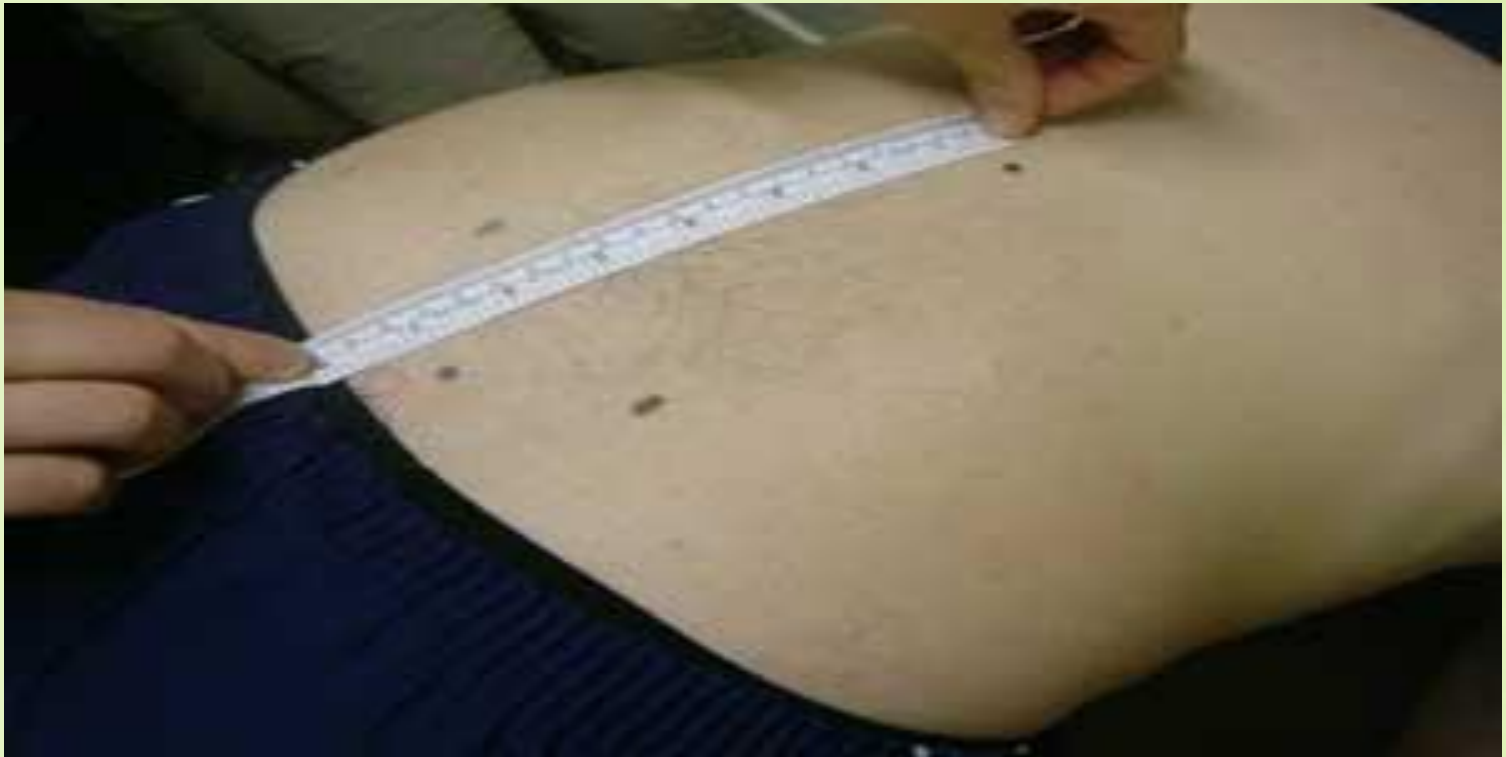- a mark is made at the level of the posterior iliac spine on the vertebral column, i.e. approximately at the level of L5.
- The examiner then places one mark 5cm below this mark and another about 10cm above this mark.



- Ask the patient to attempt to “touch their toes”.
- The distance between these two marks should be measured when the patient’s spine is flexed maximally.



- The distance should increase to more than 21cm in a normal patient.



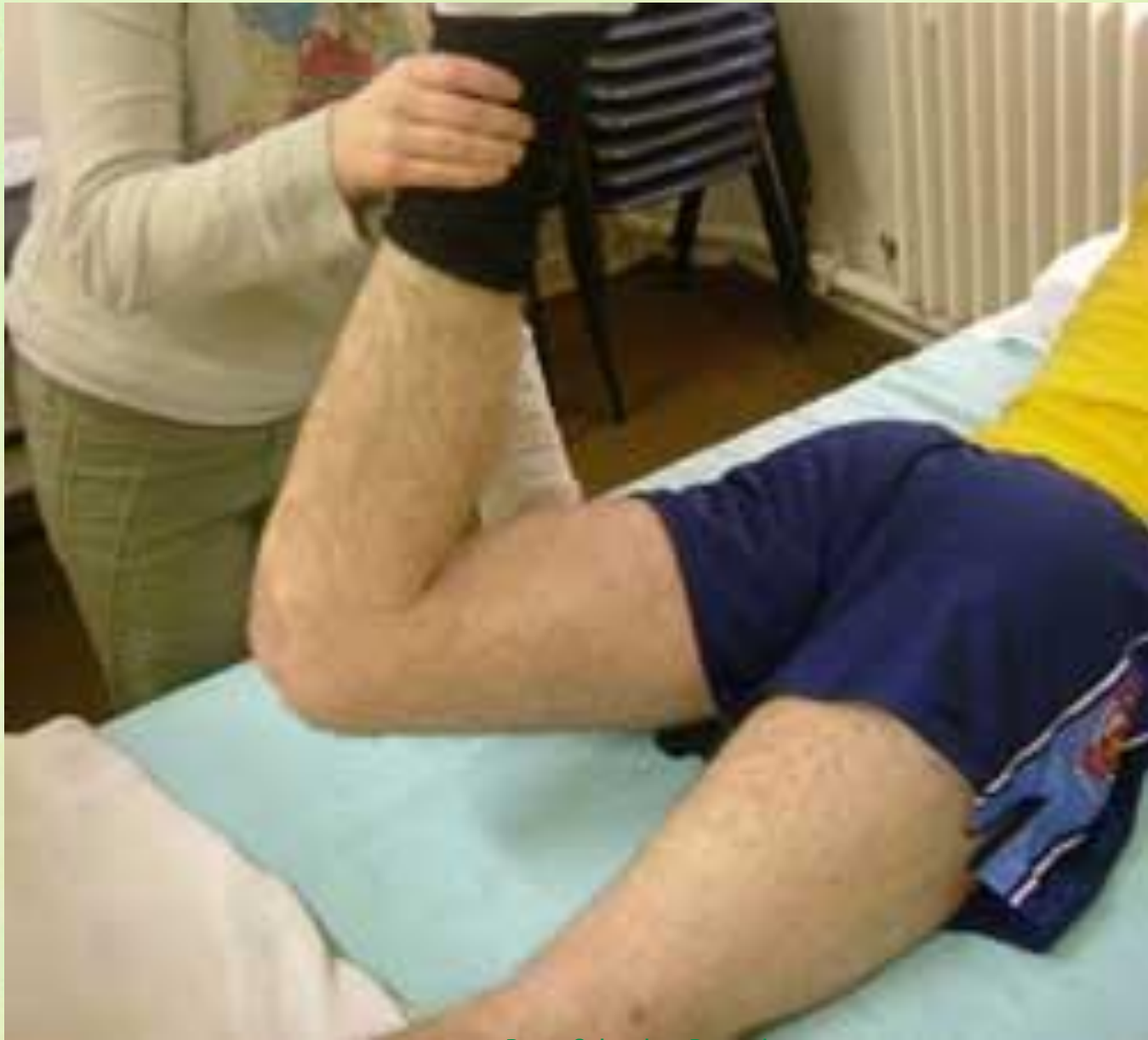- A modified way to demonstrate lumbar spine flexion is to place several fingers over the lower lumbar spinous processes and ask the patient to bend forward and touch their toes as best as possible.
- In a normal spine your fingers should move apart.

- If the increase in distance between the two fingers on the patients spine is less than 5cm then this is indicative of a limitation of lumbar flexion.
- This test allows serial measurements for patients with progressive disease to be undertaken.

# Femoral stretch

- Have the patient lie prone.
- Passively flex the knee as far as it goes. In a positive test the patient should feel pain in the ipsilateral anterior thigh (i.e. the distribution of the femoral nerve)
- Also pain may be exacerbated on hip extension.





Bone School © Bangalore

# Neurological assessment

- Neurological assessment is an essential part of the examination of the spine.
- The examination should involve a full assessment of muscle wasting, fasciculation, tone, power, coordination / proprioception, sensation and reflexes.
- perianal reflexes and sphincter tone should be tested.



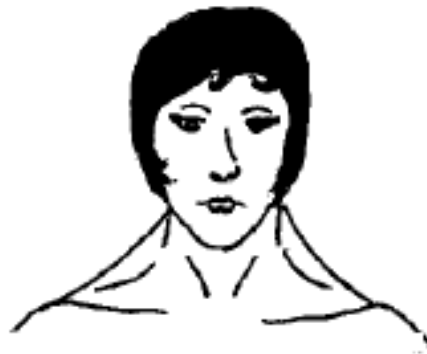# Cervical spine

# Inspection of cervical spine

- General observation at rest.
- Look for posture, symmetry (e.g. shoulder height, scapular prominence, waist, pelvis), skin (colour, scars, lesions, creases), muscle wasting, joint swelling.


# Inspection of cervical spine

- Deformity of the cervical spine is unusual.
- Characteristic features may be seen in:
- cervical spondylosis
- Klippel-Feil syndrome - congenital short webbed neck with a low hair line



Congenital webbing of the neck

- acute torticollis
- Instability of the cervical spine may easily be missed in a supine patient.
- Check that the patient can easily support their head.



**Torticollis or 'wryneck' – may be secondary to prolapsed disc**

# Inspection

- Observe the muscles for spasm or contracture.
- Contracture of the sternomastoid may be due to spasm, trauma or congenital cause.
- The latter may result in a torticollis, in which the patients holds the neck rotated to the side opposite to the lesion.

# Inspection

- enlarged thyroid gland or lymph nodes may be visible.
- An abscess may point in part of the neck.
- Instability of the cervical spine may easily be missed in a supine patient.
- Check that the patient can easily support their head.

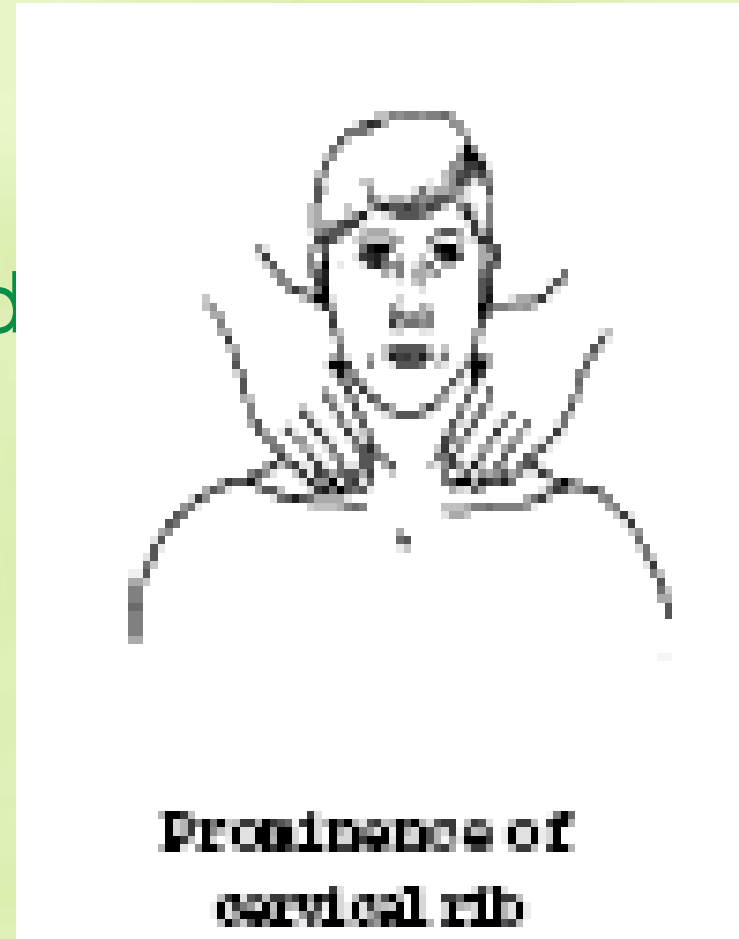


# Palpation

- Palpate for tenderness and masses.
- Palpate posteriorly in the midline, laterally, supraclavicularly - check for cervical rib - and anteriorly.
- Paraspinal tenderness radiating into trapezius is found in cases of cervical spondylosis.
- Crepitation may be evident upon flexion and extension with cervical spondylosis.
- One hand may be cold, discoloured and atrophic secondary to a cervical rib.

# Palpation

- The front of the neck should be felt for the thyroid, the anterior and posterior cervical triangles for lymph nodes.
- Back of the neck for tender areas and swellings.

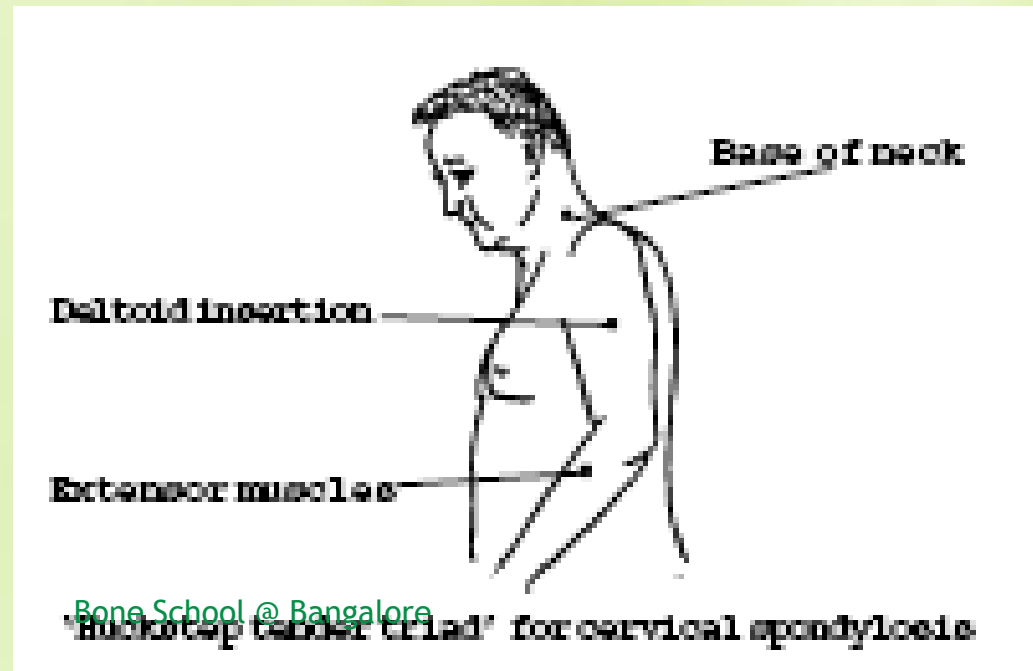


# Cervical spondylosis (CS).

- Localised areas of tenderness at the base of the neck may be present in Cervical spondylosis
- may also have radiation of pain to one or both arms to the fingers.
- Classically in CS, 3 tender areas representing the “Huckstep tender triad” should be felt for,

# Huckstep tender triad

1. At the base of the neck anterior to the trapezius
2. Over the insertion of deltoid
3. In the extensor mass of the forearm.

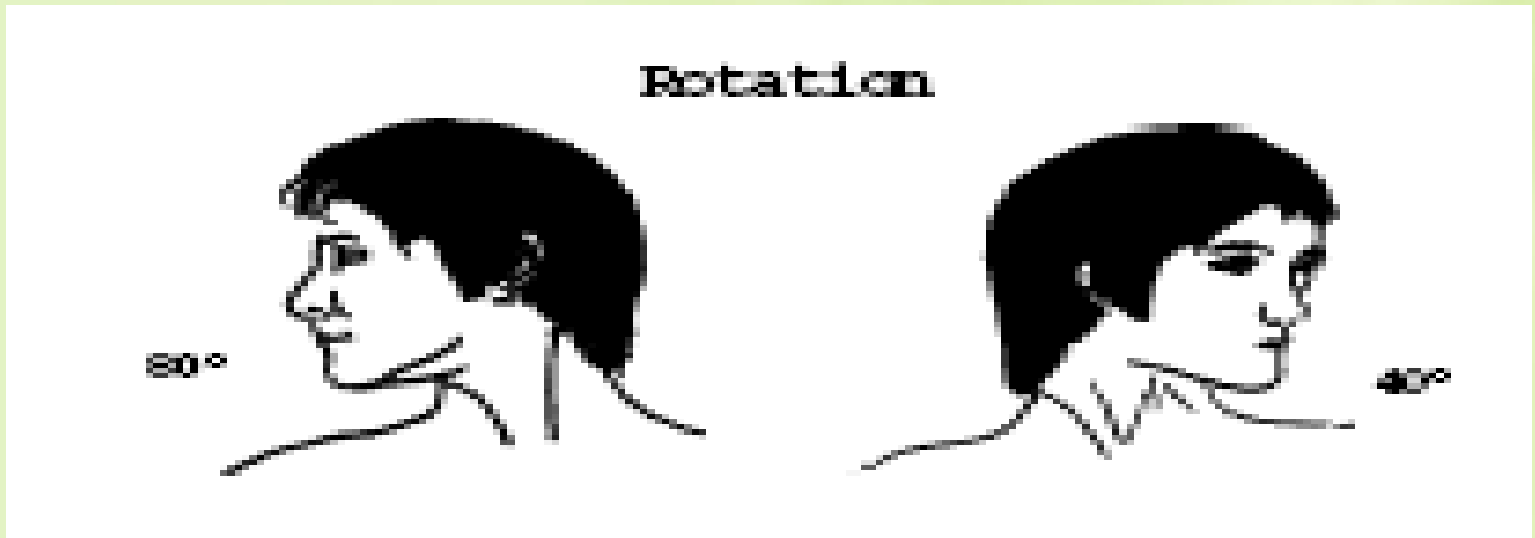


# Movements

- ***Active range of motion.*** Ask the patient to move their neck in the following directions:
- flexion - note chin distance to sternum
- extension - note how many degrees the facial plane is beyond the vertical
- rotation - note in degrees
- lateral flexion - note in degrees
- Also test active shoulder range of motion as neck and shoulder symptoms may overlap.
- ***Passive range of motion.*** Only if active range not full; do in supine position.


# rotation

- Should be equal
- About 70-90% to each side.



# Flexion and extension

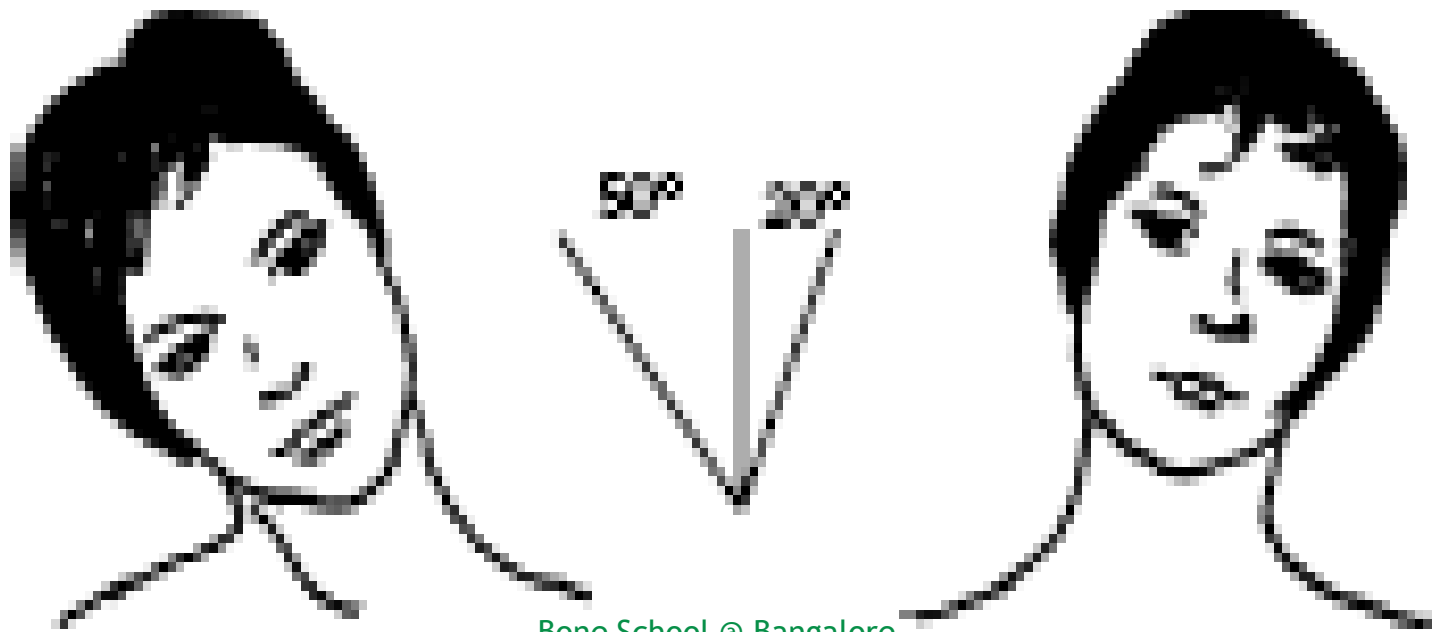
- Full flexion when chin touches the chest
- Full extension of at least 30° beyond the horizontal should be possible.
- Usually greater in young people.



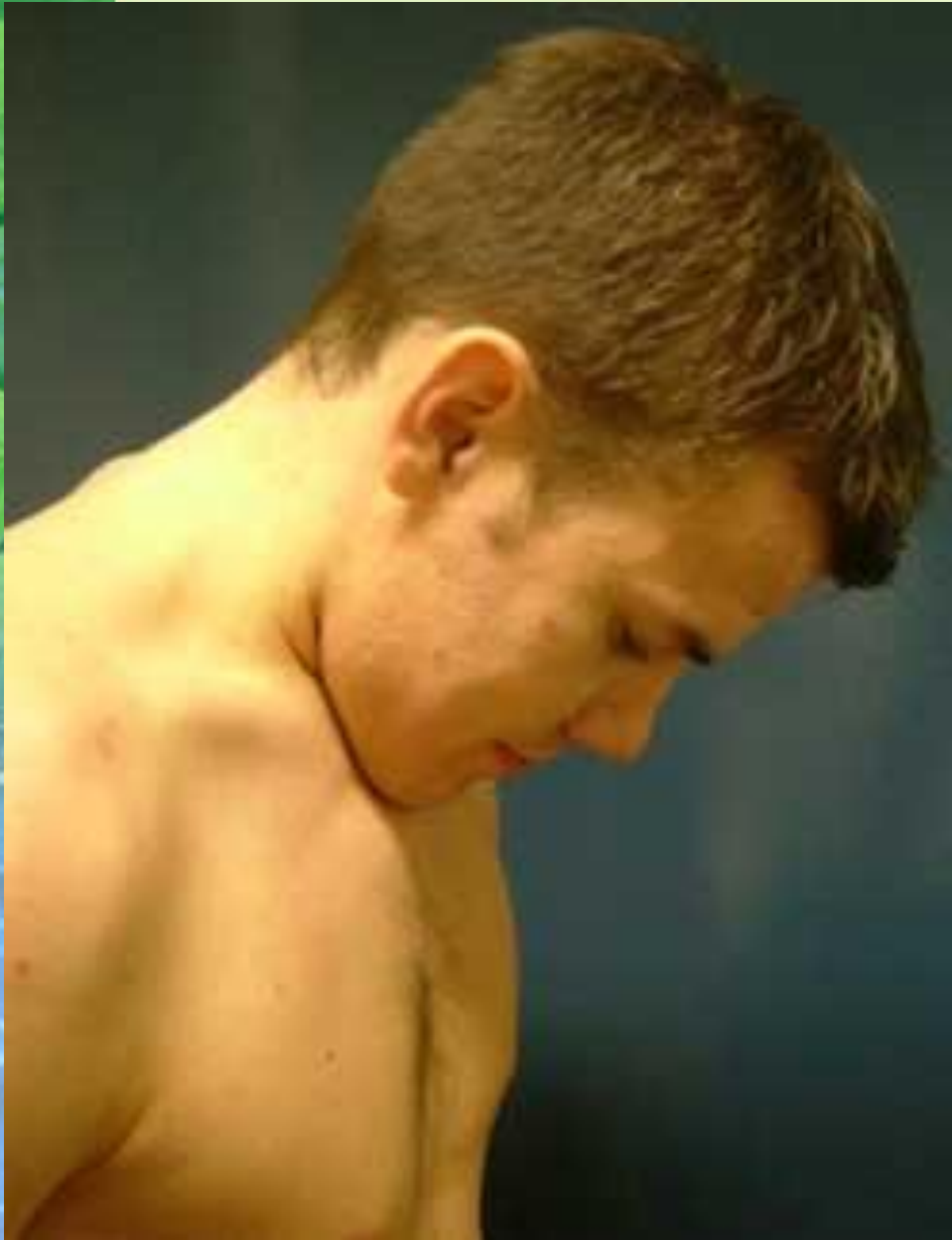# Lateral flexion

- At least 40\* to each side.

## Lateral flexion



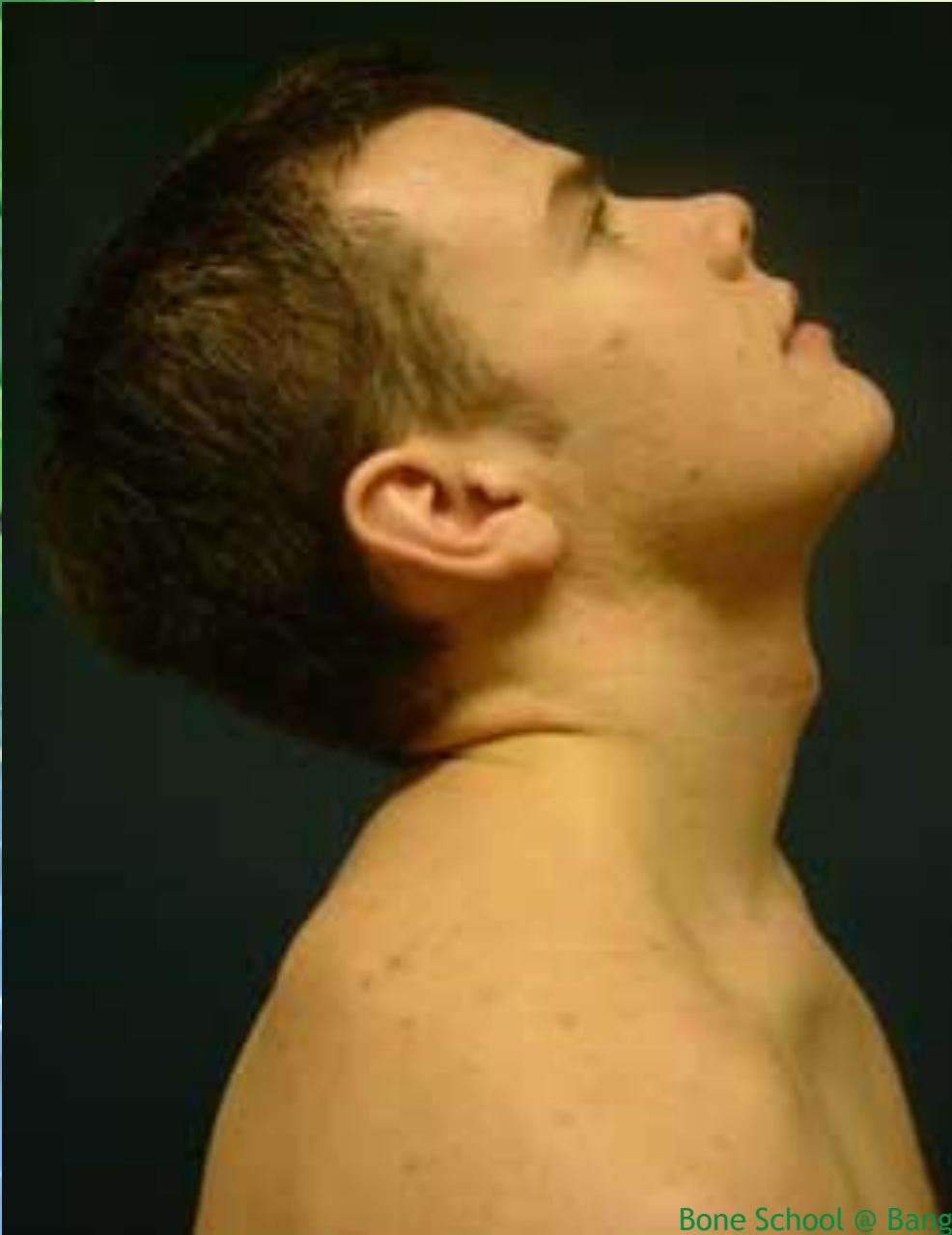



- Cervical spine flexion  
“Touch your chin on your chest”

# Measurement

- ask the patient to flex and extend head
- a spatula held in the mouth acts as a pointer to enable the range of movement to be measured by goniometer: normal range is 130 degrees.
- The occipito-atlantoid joint is primarily involved.

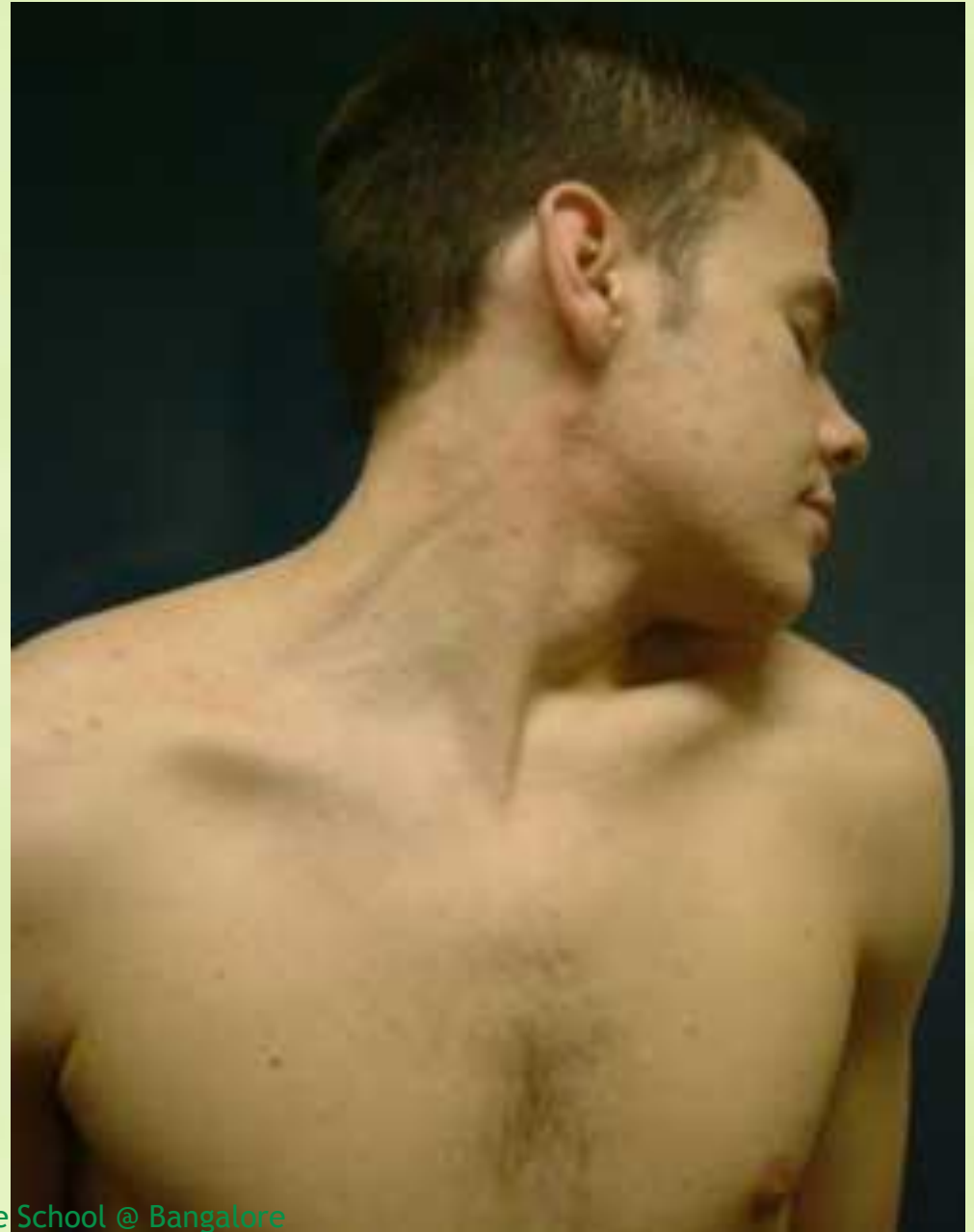

- Cervical spine extension  
“Look up and back”

- Lateral cervical spine flexion  
“Touch your shoulder with your ear”  
(Both sides)



- Lateral cervical rotation (Both sides)  
“Touch your shoulder with your chin”



- lateral flexion: ask the patient to tilt his head laterally from a neutral position; normal range is 45 degrees.
- Whole of cervical spine involved.
- rotation: ask the patient to look over his shoulder –
- normal range is 80 degrees to either side.
- Rotation is a function of the atlanto-axial joint.

# NEUROLOGICAL EVALUATION

## Motor Assessment (Cervical)

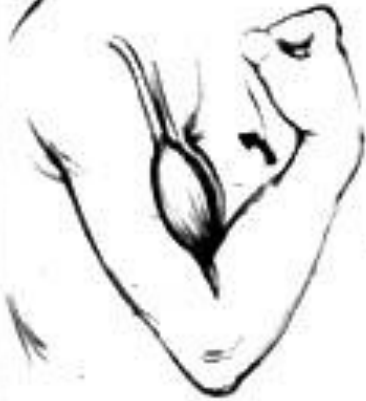C1/C2	suboccipital triangular muscle
C3/C4	diaphragm
C5	deltoid/shoulder int/ext rotators
C6	brachioradialis/wrist extensors ECRL/ECRB
C7	triceps, finger extensors (EDC)
C8	finger flexors (FDS/FDP)
T1	interossei

# MOTOR

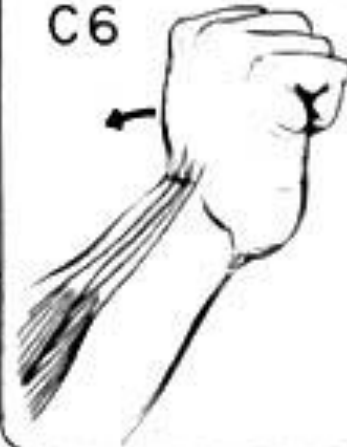DELTOID  
C5



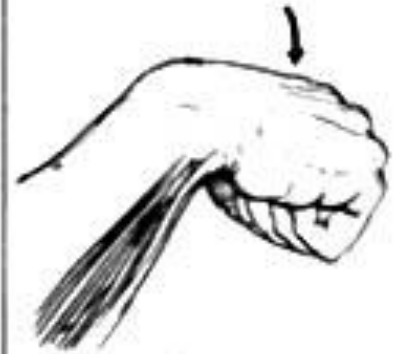BICEPS  
C5,6



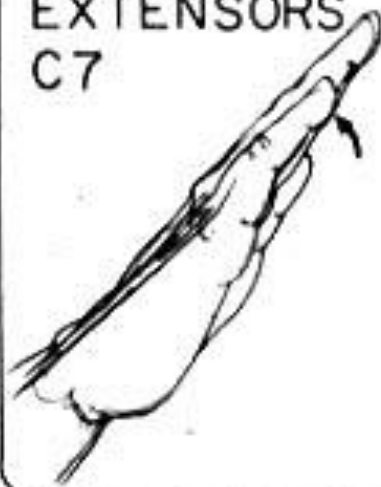
WRIST  
EXTENSORS  
C6



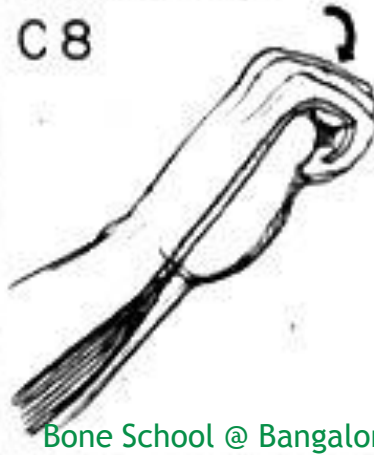WRIST  
FLEXORS  
C7



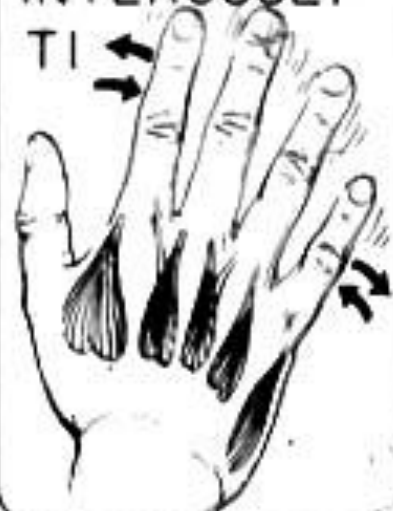FINGER  
EXTENSORS  
C7



FINGER  
FLEXORS  
C8



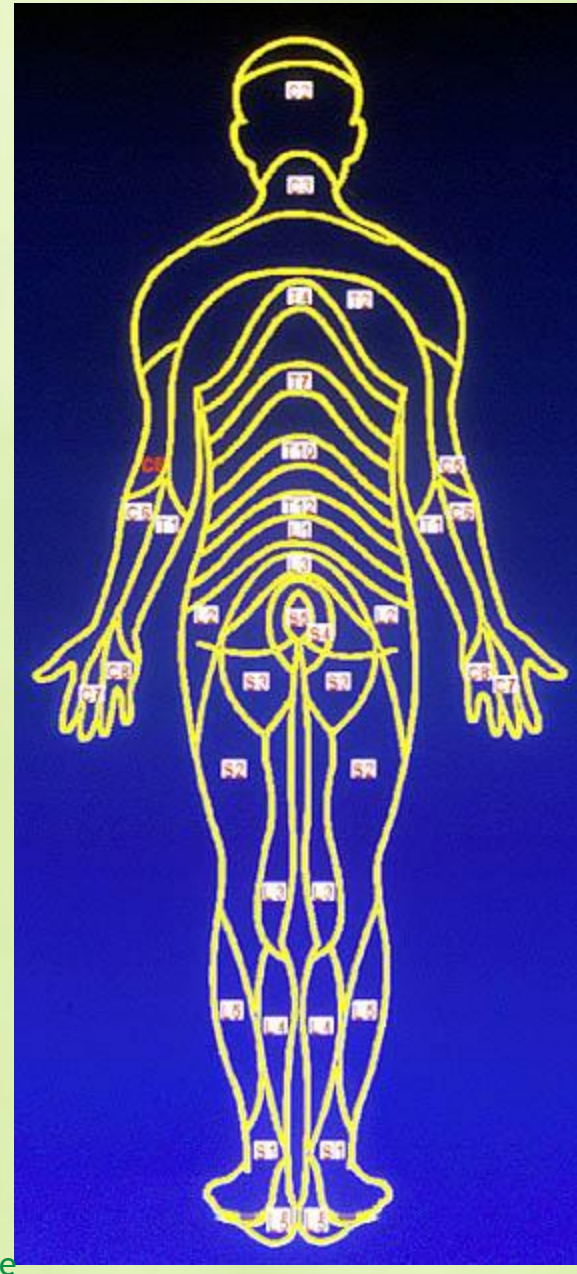
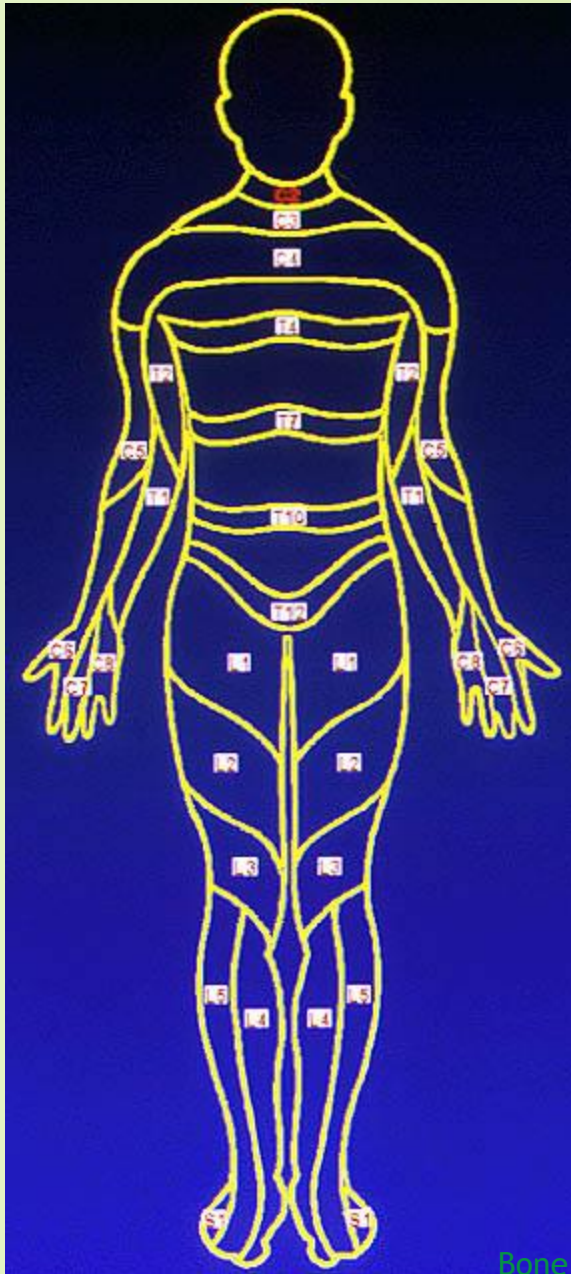
INTEROSSEI  
TI





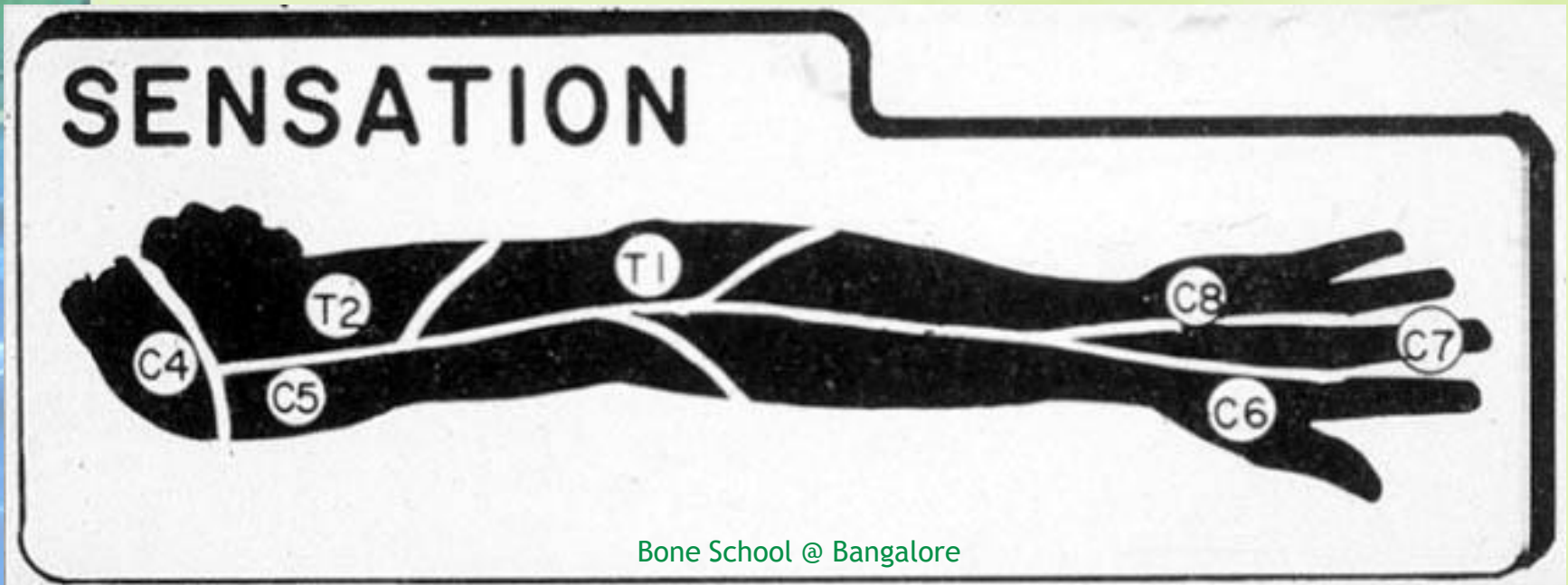
# SEGMENTAL NEUROLOGY

- When examining the cervical spine it is essential to examine the segmental neurology.
- Root lesions may be indicated by weakness in the upper limbs in a segmental distribution, with loss of dermatomal sensation and altered reflexes.
- If cervical cord compression is suspected the lower limbs should also be examined specifically looking for upgoing planters and hyperreflexia.



# *Sensation.*

- Know your C5 to T1 dermatomes.
- Test light touch and sharp/dull sensation.



# Sensory Assessment (Cervical)


C1/C2	Occiput to nape of neck
C3/C4	Posterior neck and superior shoulder
C5	deltoid region of arm
C6	radial aspect of forearm/thumb/index finger
C7	middle digit
C8	ring/fifth digit/ulna forearm
T1	medial upper arm/axilla

# REFLEXES

- *Muscle stretch reflexes.* Test the following reflexes:
- Biceps - C5/6
- Brachioradialis - C5/6
- Pronator - C 6/7
- Triceps - C7/8



# Thoracic spine

- 
1. Inspection
  2. Gait
  3. Movements
  4. Sitting examination
  5. Supine examination
  6. Prone examination

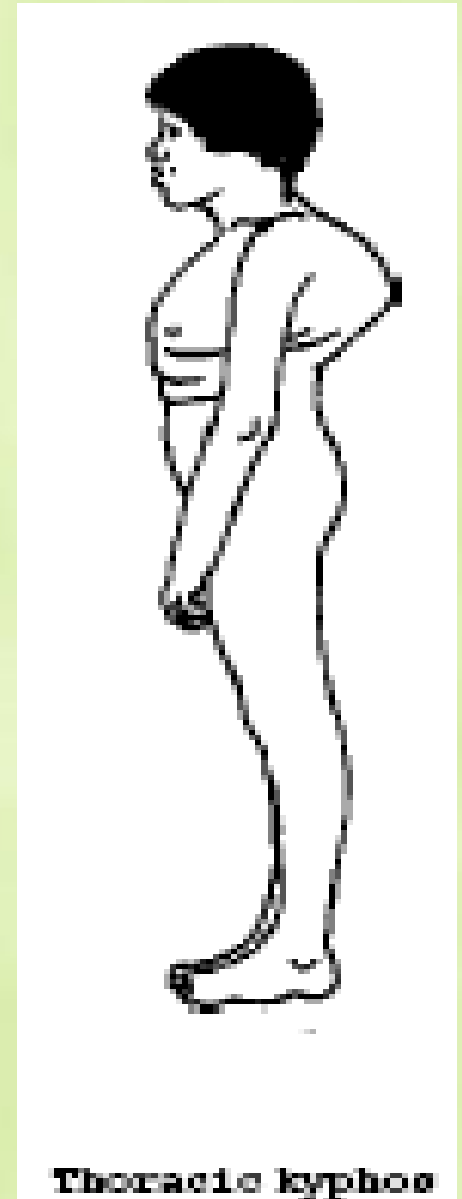
# Inspection of thoracic spine

- General observation of the standing patient.
- Look for posture, symmetry, leg length discrepancy, skin (colour, scars, lesions, creases), muscle wasting, joint swelling.
- *Gait.*
- Have the patient walk normally then on their toes (tests S1) then on their heels (tests L4/5).
- Observe for abnormal gait patterns including
- Antalgic, Trendelenburg, Short leg, Foot drop



# Deformities

- Deformities of the thoracic spine are both common and important.
- Scoliosis:
- Kyphosis:
- Lordosis:
- this may be seen but is rarely a serious problem



# Inspection of lumbar spine

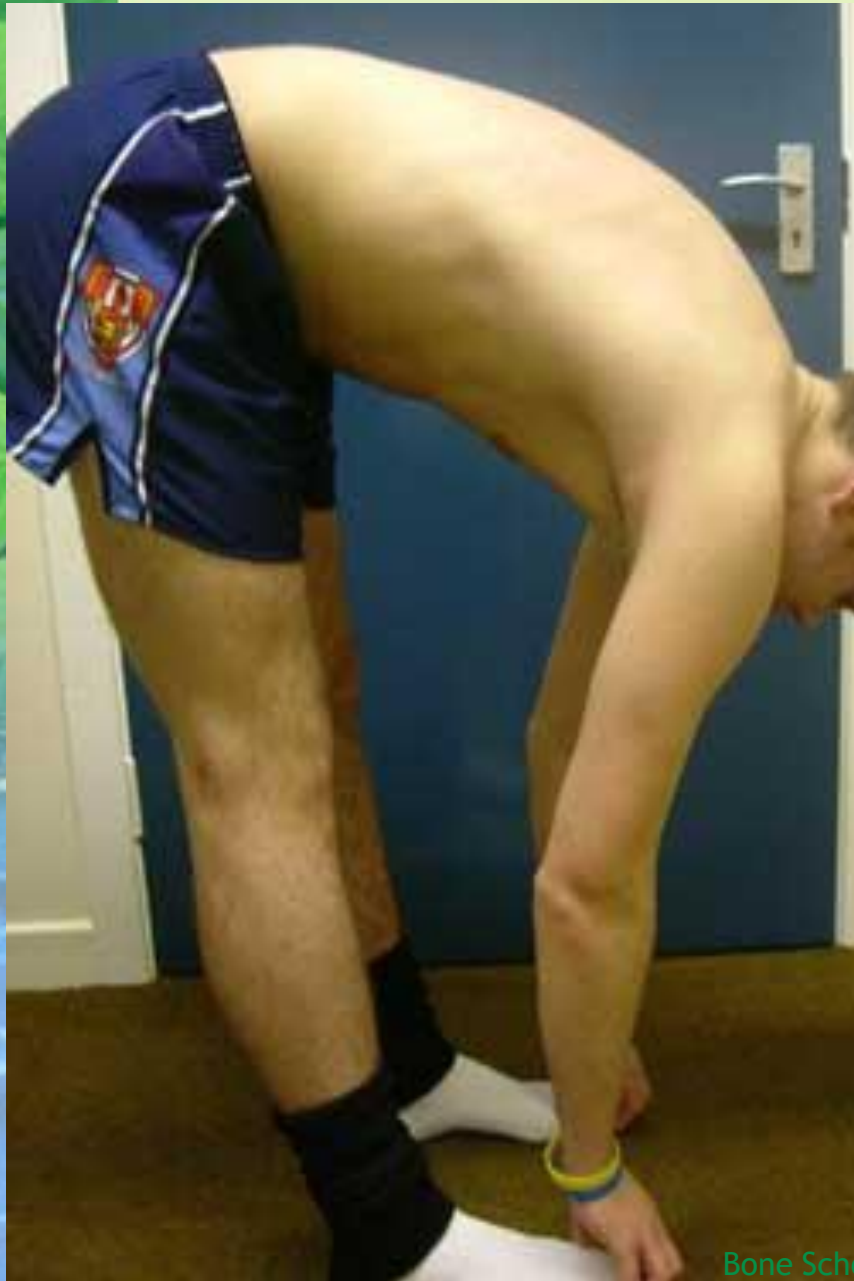- scoliosis is best seen with the patient leaning forward.
- The normal lordosis of the lumbar spine may be flattened by muscle spasm.
- Accentuation of the lordosis is rarely serious.

# Thoracic spine

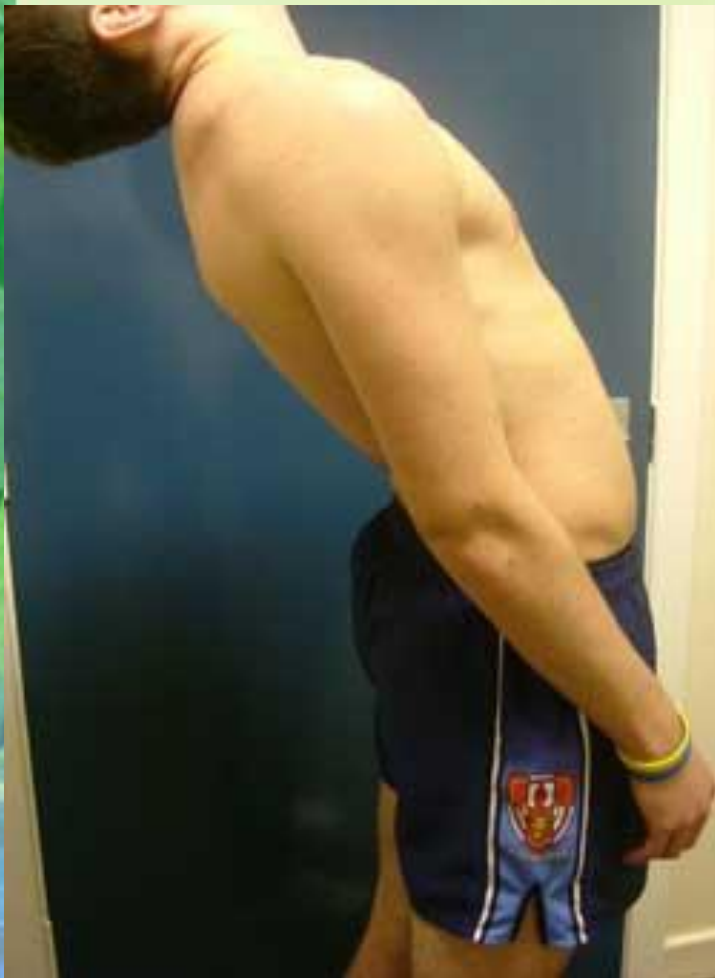- Tenderness is elicited by light percussion of the spinous processes of the thoracic spine, with the patient leaning forward.
- Rotational stress from the side.
- in cases of lumbosacral junctional spondylolisthesis tenderness may be accompanied by a palpable step.

# Active range of motion.

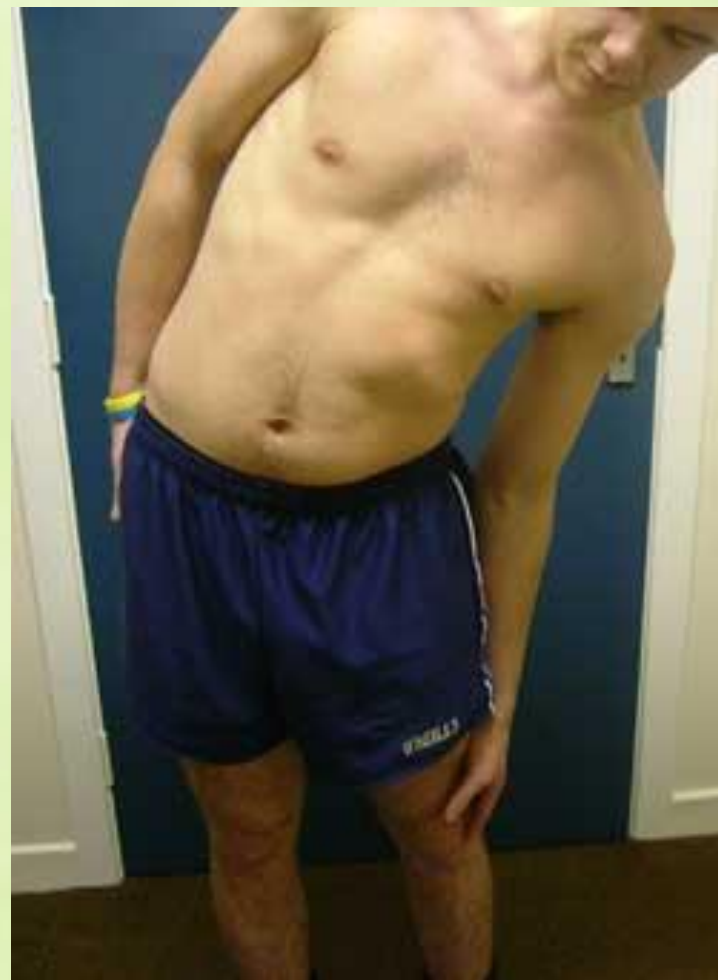- Ask the patient to perform the following manoeuvres:
- Forward flexion - note the finger tip to floor distance
- Extension - record as a % of normal



Lumbar flexion  
“Try to touch your toes  
without bending  
knees”



**Lumbar extension**  
**Lean back”**



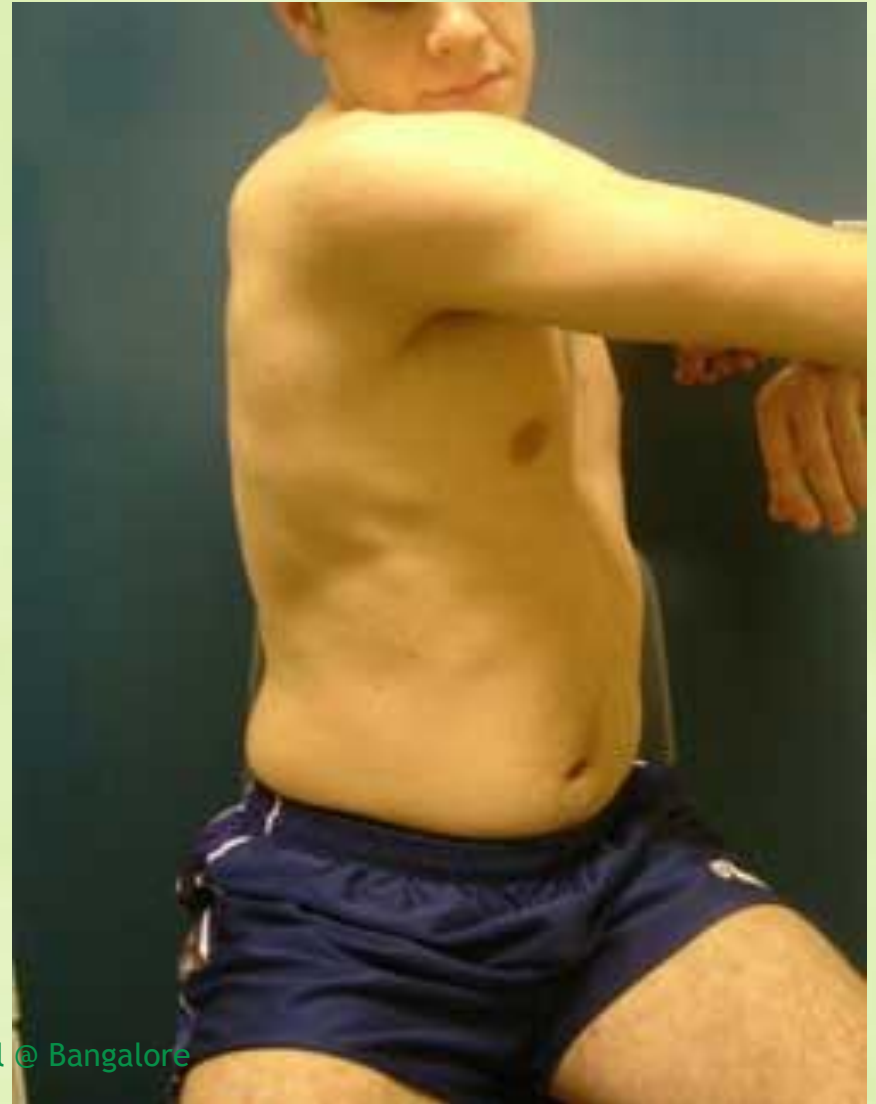**Lateral lumbar flexion (Both sides) “Slide your hand down your leg”**

**Lateral flexion - note the finger tip to floor distance**

Bone Joints © Bangalore

# Thoracolumbar rotation

- Rotation - record using degrees
- “Sit down and turn round, looking over your shoulder” (Sitting down helps fix the patients pelvis)



# Sitting examination.

- Perform the following examinations:
- Straight leg raising
- Muscle stretch reflexes
  - Quadriceps - L4
  - Gastroc/soleus - S1
- Muscle power
  - Knee extension - L3/4
  - Knee flexion - L4/5



# Supine examination.

- Perform the following examinations:
- Straight leg raising
- reflexes
- Muscle power
- Examine hip joints
- Examine sacro-iliac joints



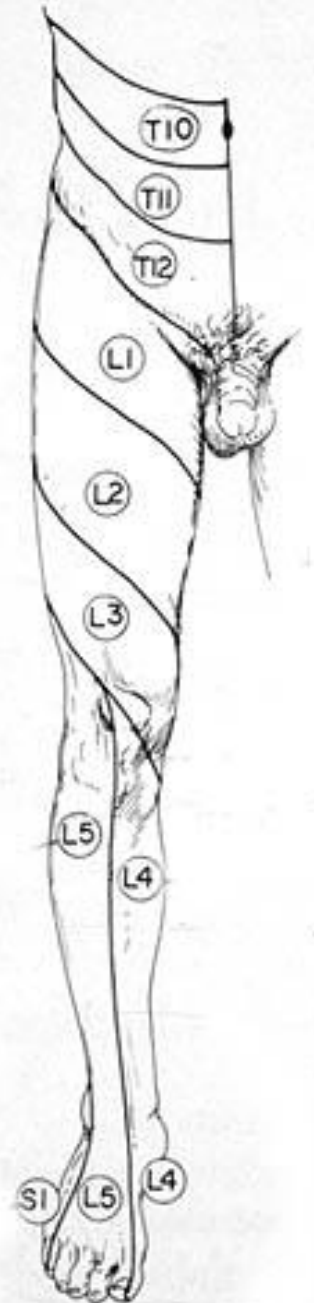
## Sensory Assessment (Thoracic)

- T4 - Nipple line
- T7 - Xyphoid Process
- T10 - Umbilicus
- T12 - Groin

- Sensation
- Know your L4 to S1 dermatomes
- Light touch, sharp/dull sensation

## Sensory Assessment (Lumbosacral)

- L1/L2 Inguinal region/inner thigh
- L3/L4 Anterior/anterolateral knee/medial calf
- L5 Lateral calf/Dorsal foot
- S1 posterior calf/lateral and plantar foot
- S2-S5 perineum

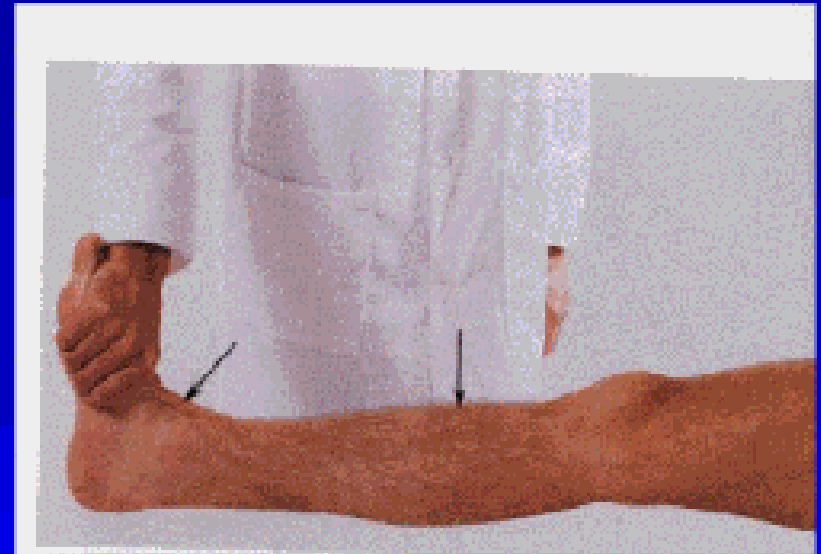


# Prone examination

- Perform the following examinations:
- Muscle power
  - Hip extension with knee flexed - S1
- Prone extension test (femoral stretch test)
- Palpation

# L4 Root Compression

- Decreased strength in ankle dorsiflexion (tibialis anterior) and also in leg extension (quadriceps)
- Decreased sensation along medial aspect of lower leg
- Decreased patellar reflex and problem with heel walking



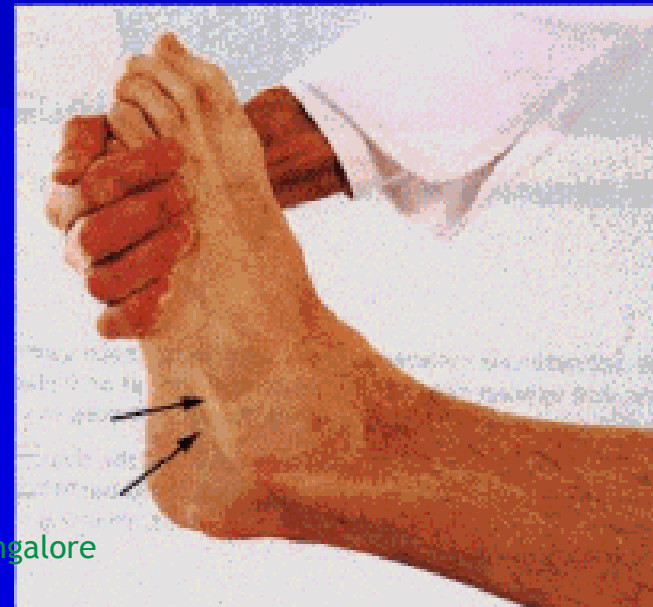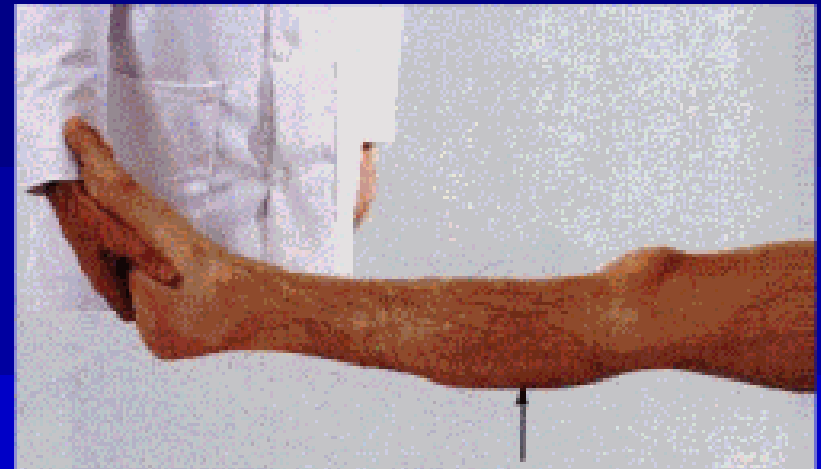# L5 Root Compression

- Weakness of extensor hallicus longus and extensor digitorum longus
- Decreased sensation along lateral leg and web of great toe



# S1 Root Compression

- Weakness in plantar flexion (gastrocnemius and soleus) and weakness with eversion of ankle
- Decreased sensation along lateral foot, plantar aspect of foot and heel
- Decreased ankle reflex



# Reflexes

Important in determining the nature (cord vs peripheral nerve) and the extent (partial vs complete) of neurologic injury



# Reflex Assessment (Thoracic)

T7-T10 - Upper Quadrant Abdominals

T10-L1 - Lower Quadrant Abdominals

# Reflexes (Lumbosacral)

L1 - Lower Abdominals; Cremasteric Reflex

L2/L3/L4 - Patellar Tendon (mostly L4)

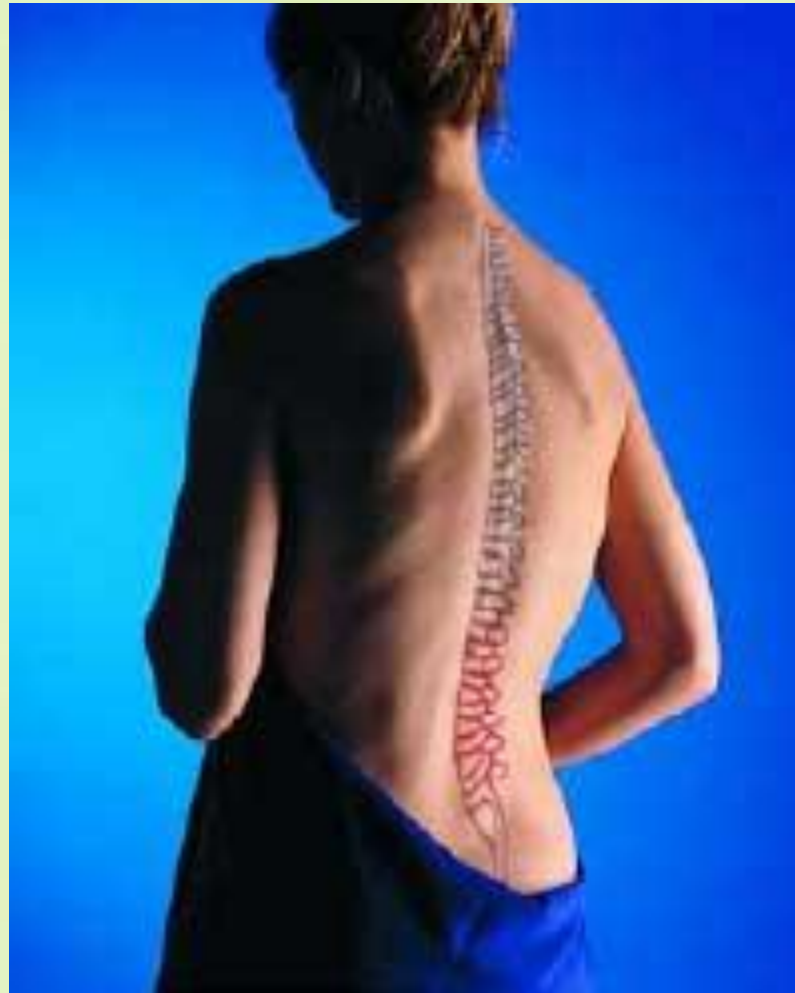L5 - None

S1 - Achilles Tendon

S2/S3/S4/S5 - Superficial Anal Reflex  
(Wink)

# Some tips

- get the patient to stand on their toes, thus checking plantar flexion of the foot and the S1 nerve root.
- If necessary, test each foot separately, giving them some support with an outstretched arm.
- Ask them to rock onto their heels - test of L4/L5



**hope that was useful to you**

Bone School © Bangalore

