

# Clinical Examination of SPINE

Rajagopalan

Professor & HOD, Dept. of Orthopedics  
Raja Rajeswari Medical College & Hospital,  
Bangalore



Pearson International Edition

Physical  
Examination  
of the Spine  
& Extremities

Stanley Hoppenfeld

# Clinical examination of spine

- History
- Inspection
- Palpation
- Movement and measurement
- Neurology of the limbs

# History

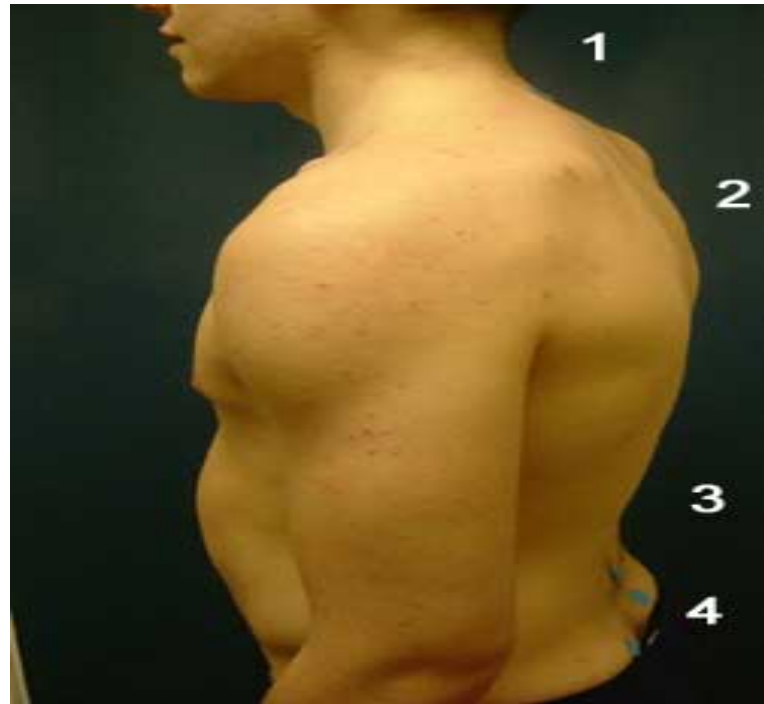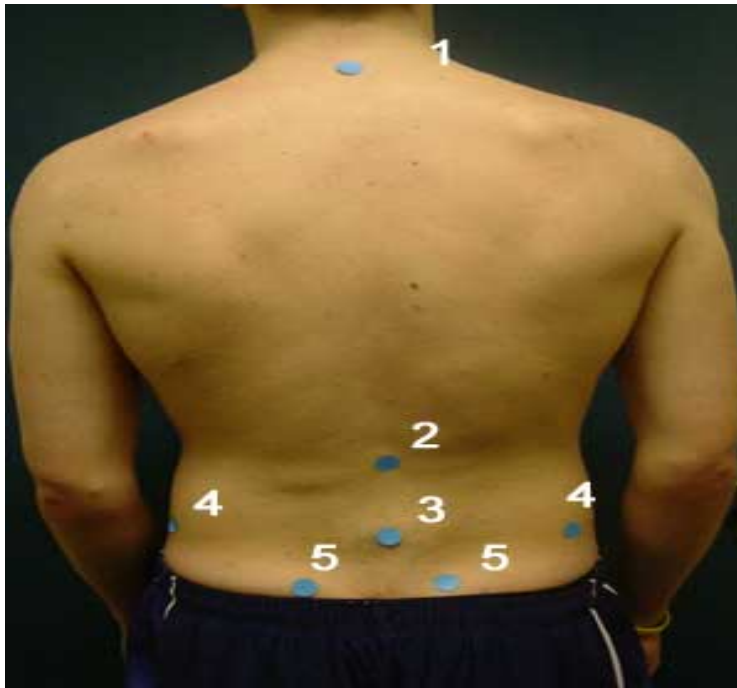
- Injury : type, violence, mechanism (direct, indirect, rotational) site.
- Pain: onset, nature, site, radiation,
- Deformity
- ADL
- Bladder / bowel function
- Treatment

# Inspection

- Start with the patient standing, then lying prone and finally lying supine.
- General observation
  - Does the patient look well?
  - Assess the patient's posture - any obvious conditions?

# Patient Standing

- Remember to inspect from all sides (front, laterally and from behind):

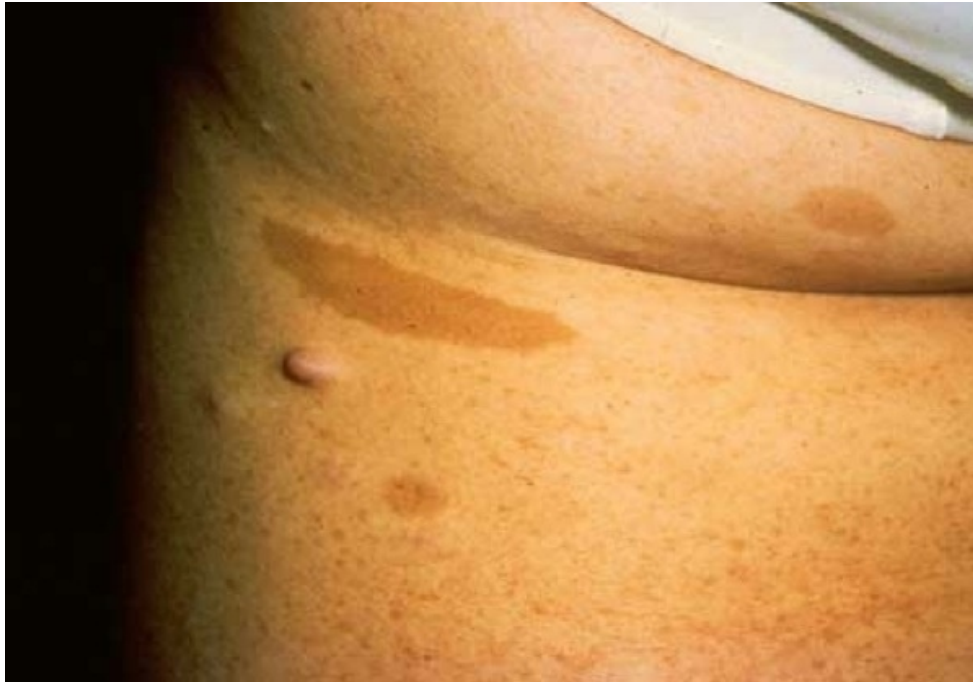

# Inspection

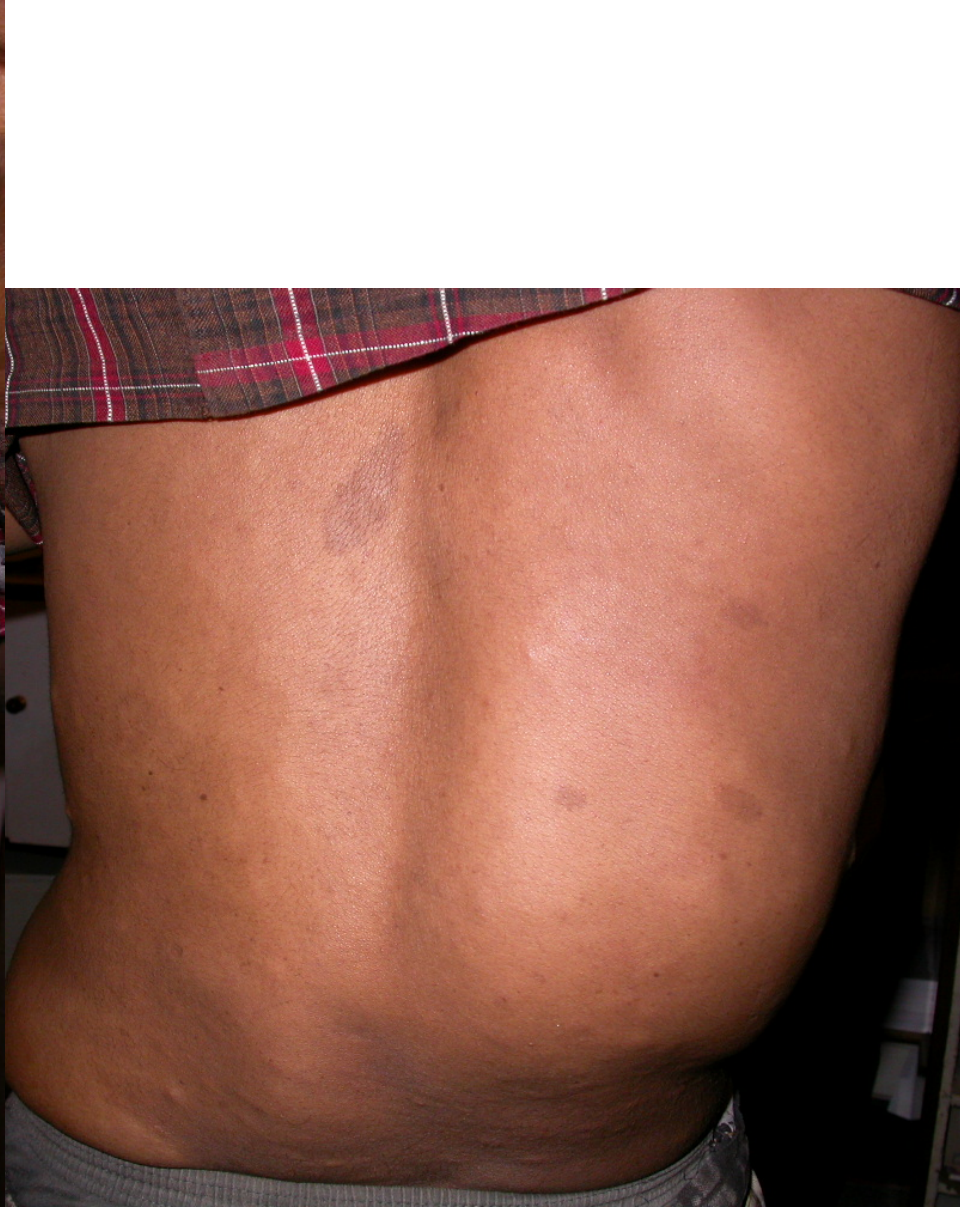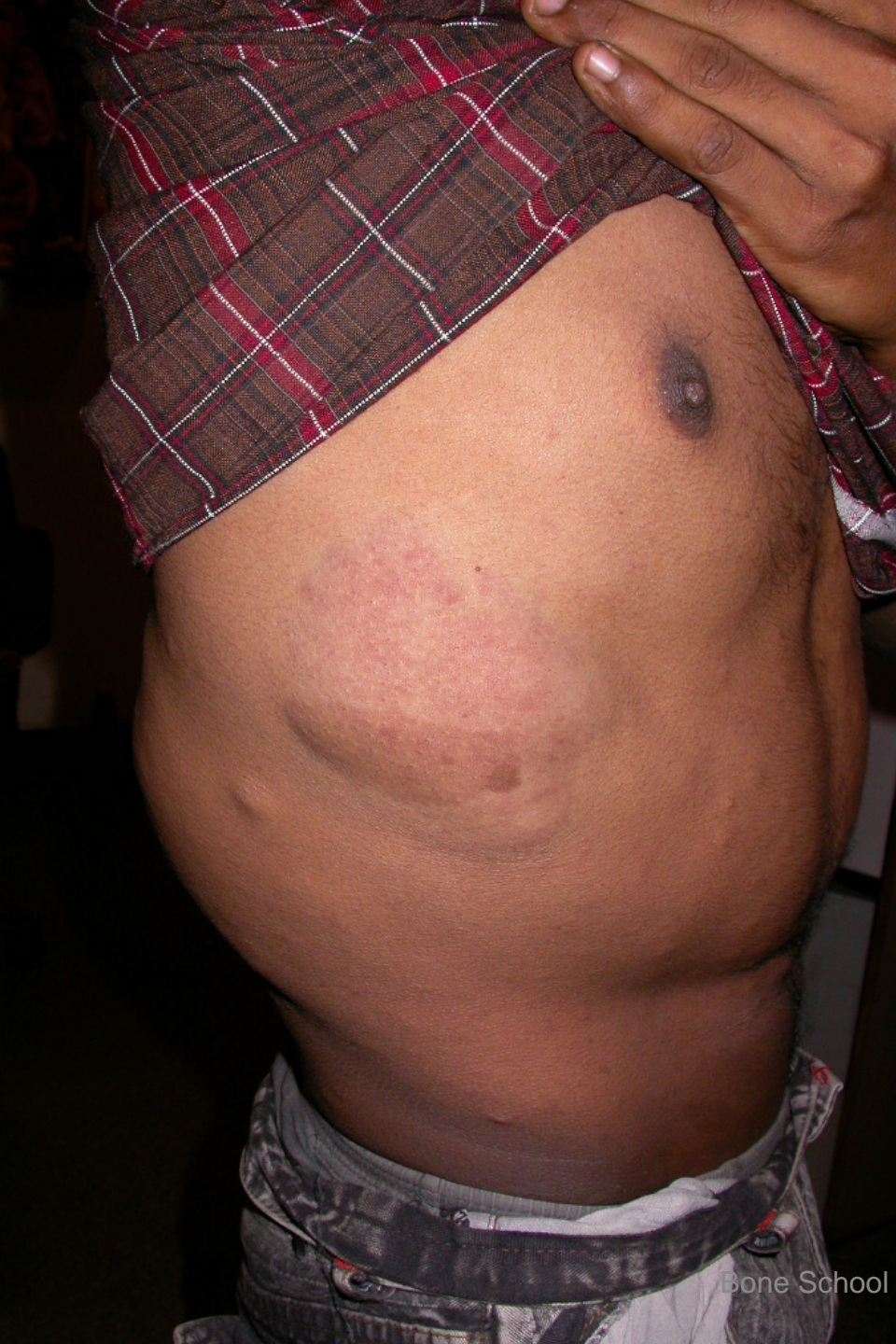1. Attitude and deformity
2. Position of head, shoulder, scapula
3. Rib hump
4. swellings, sinus, skin
5. Gait

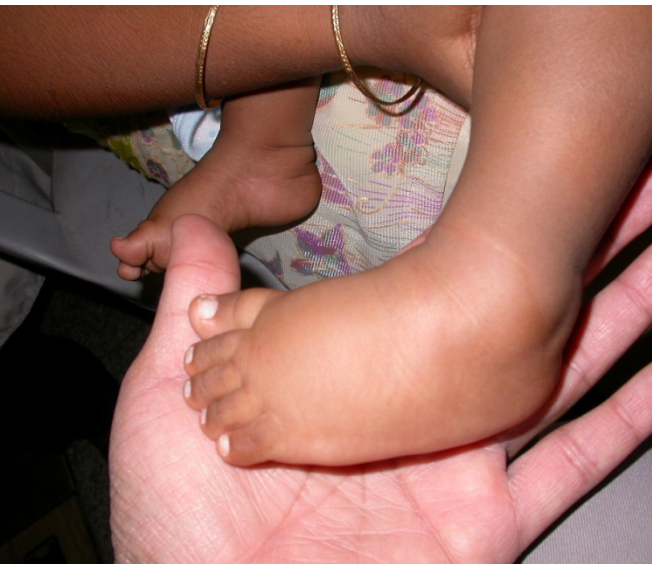- Skin
  - Scars (surgical scars)
  - Sinuses (deep infection)
  - Unusual skin creases
  - Pigmentation
    - Cafe au lait spots (Neurofibromatosis)
    - Hairy patch (spinal dysraphism)
    - Mongolian Blue spot (no clinical significance - more common in asians)

# Cafe au lait spots Neurofibromatosis

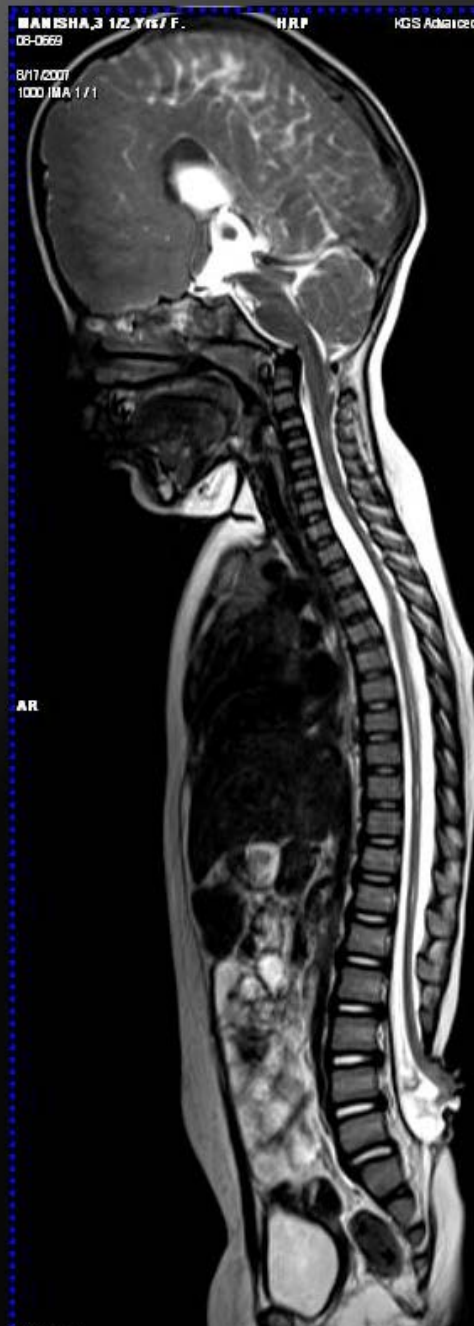






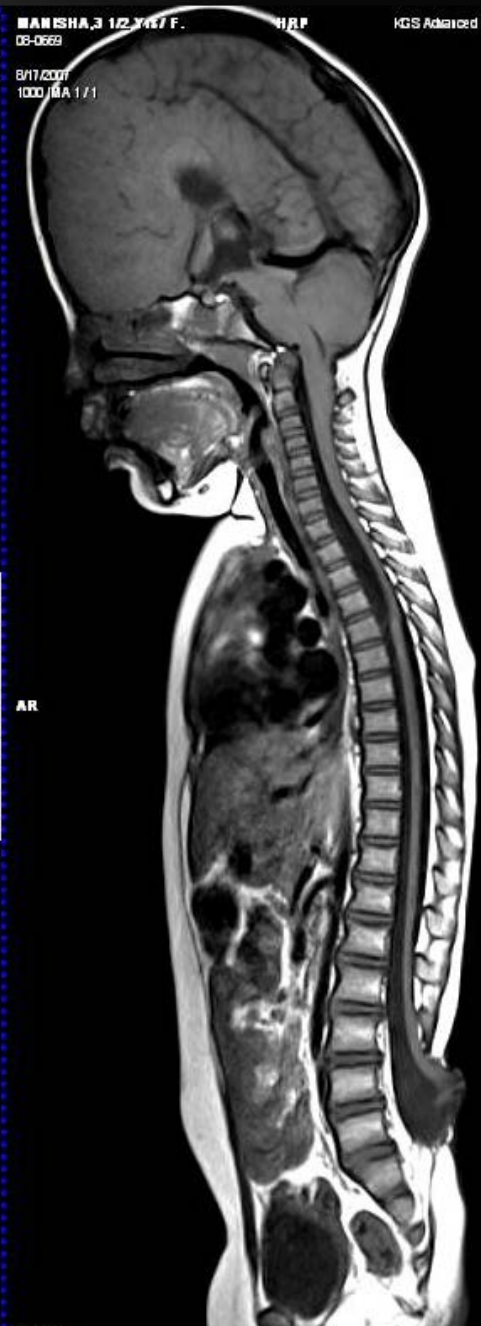
MANISHA, 3 1/2 Yrs F. HRP  
08-0669  
B/M/2007  
1000 JMA 1/1

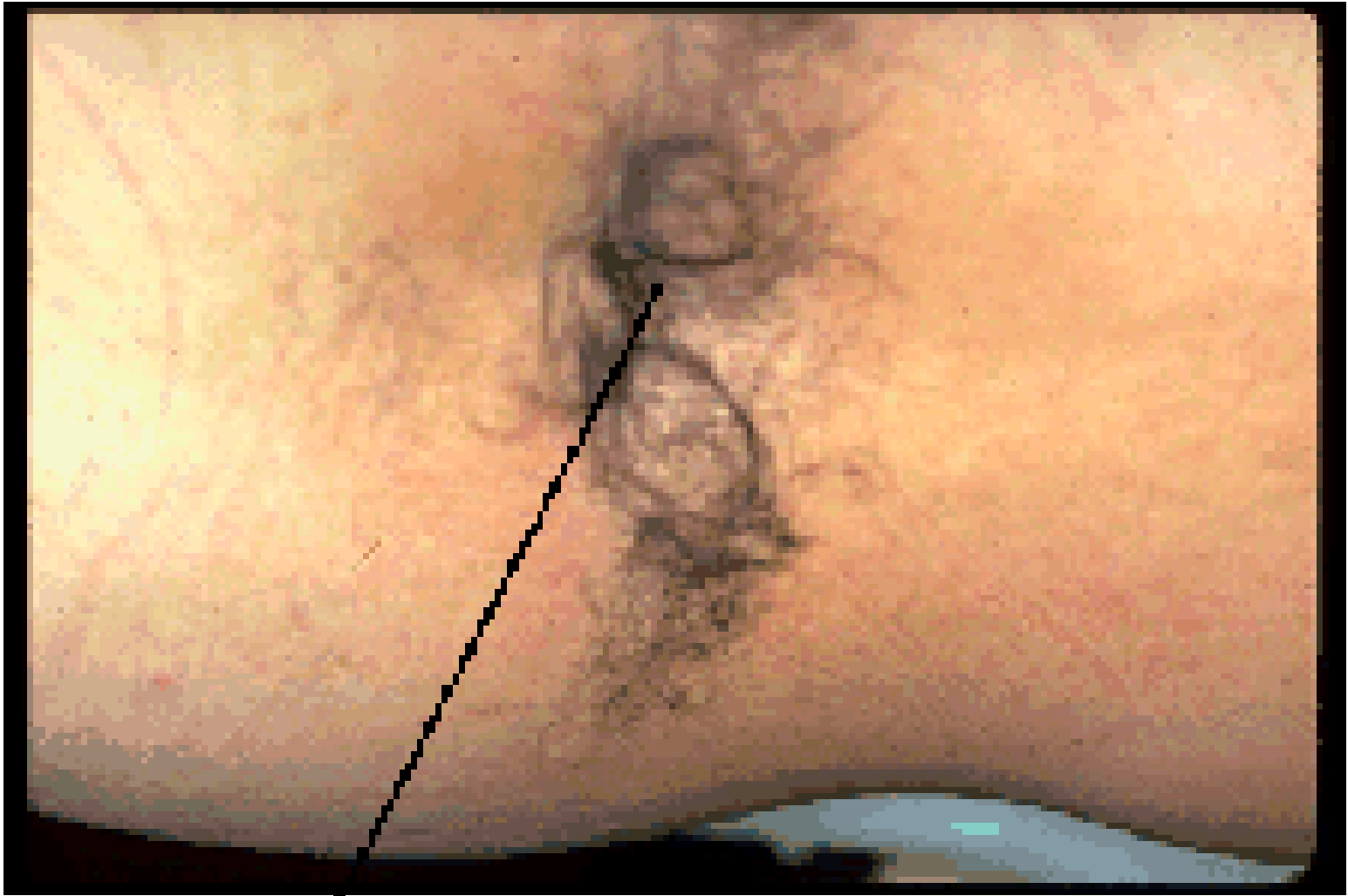

TR 4230.0  
TE 105.0  
p2 M/N/O R/M/CV12/D IS2D  
\*te R2d1r25  
Bone School @ Bangalore

KGS Advanced MR & CT Scan  
Aka1b  
HFS  
+LPH  
MANISHA, 3 1/2 Yrs F. HRP  
08-0669  
B/M/2007  
1000 JMA 1/1

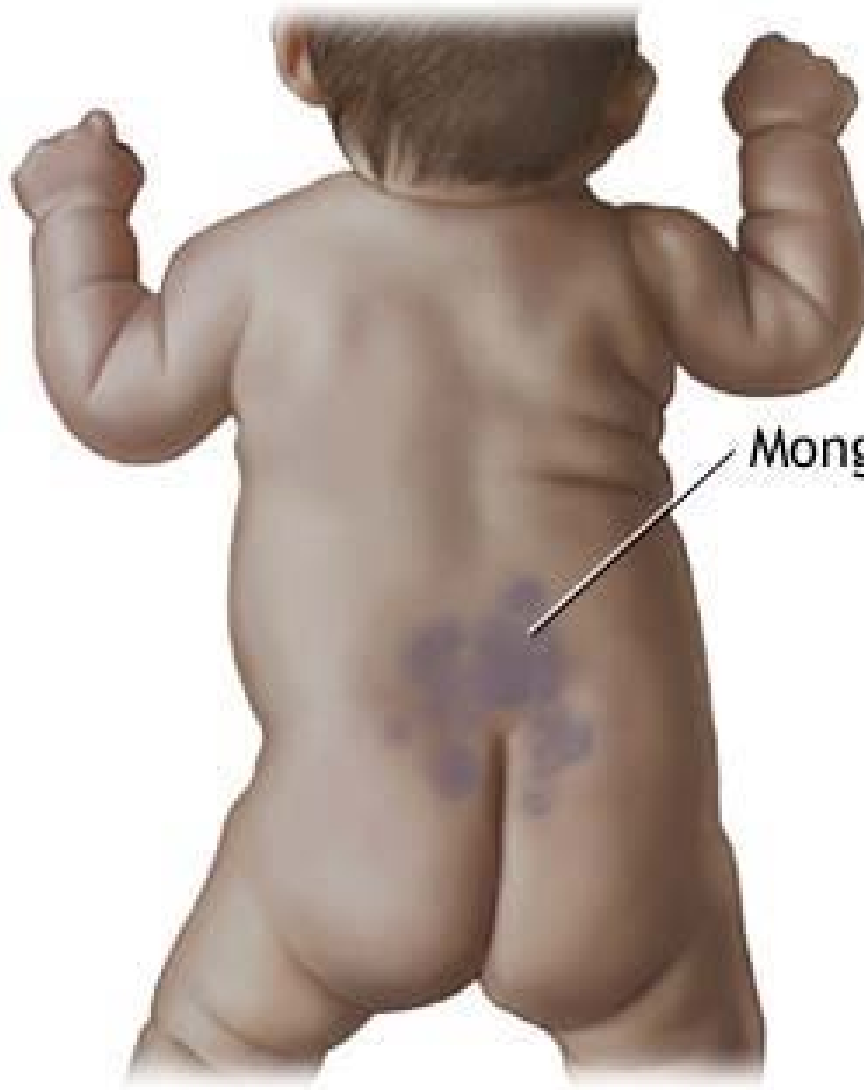


TR 611.0  
TE 11.0  
p2 M/N/O R/M/CV12/D IS2D  
\*te R2d1\_3



# Hairy Patch

Bone School @ Bangalore

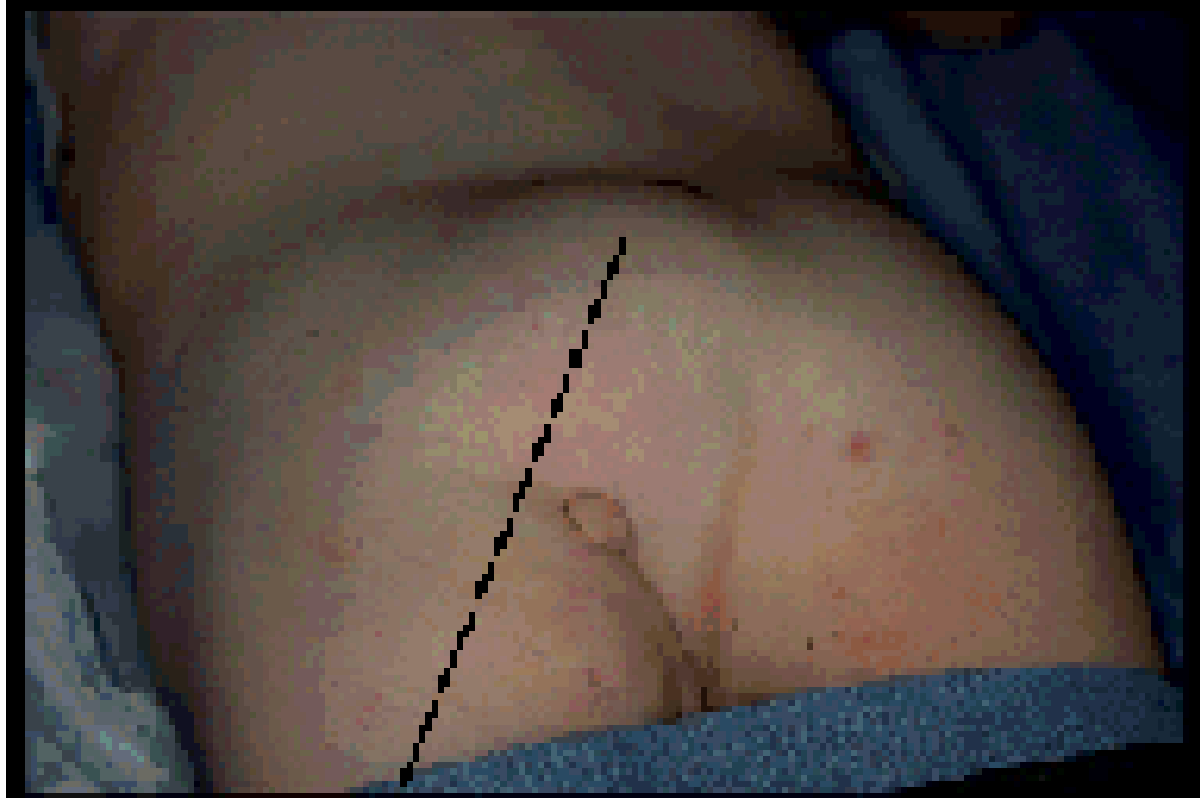


Mongolian blue spots

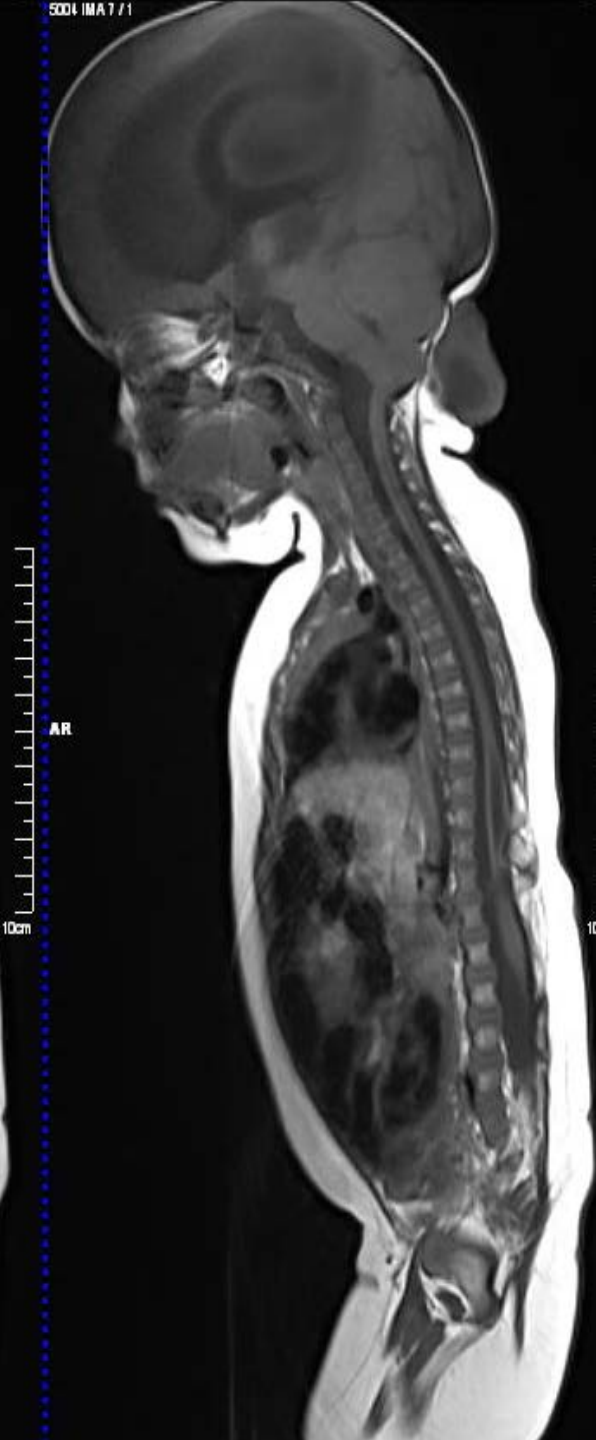
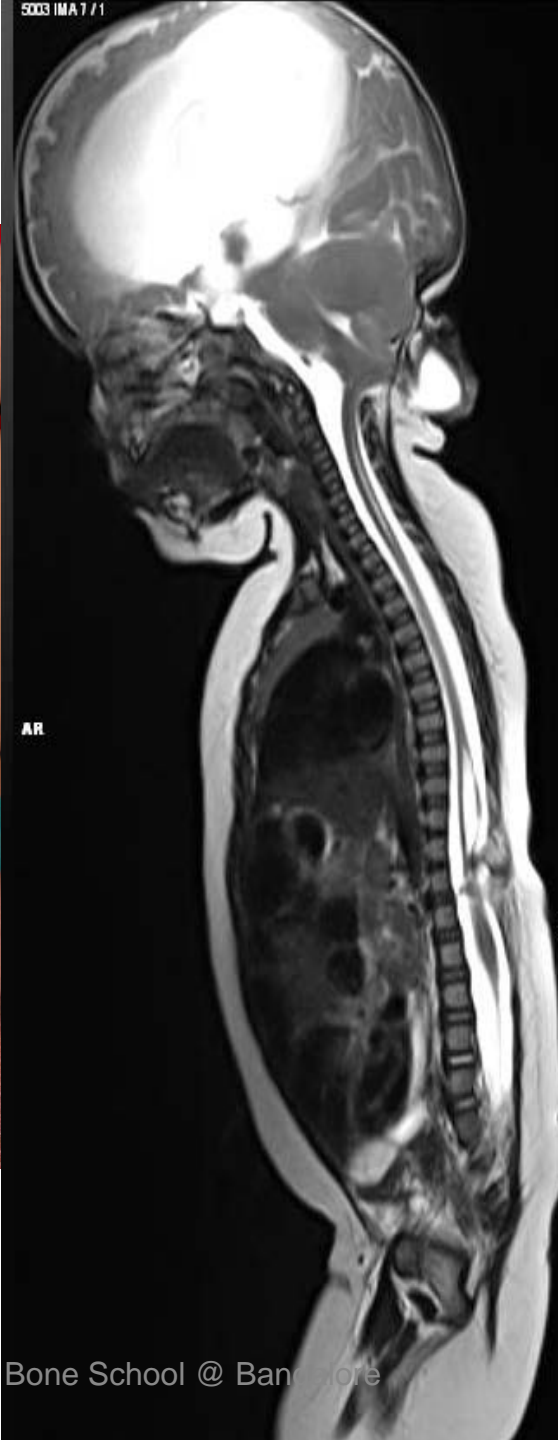
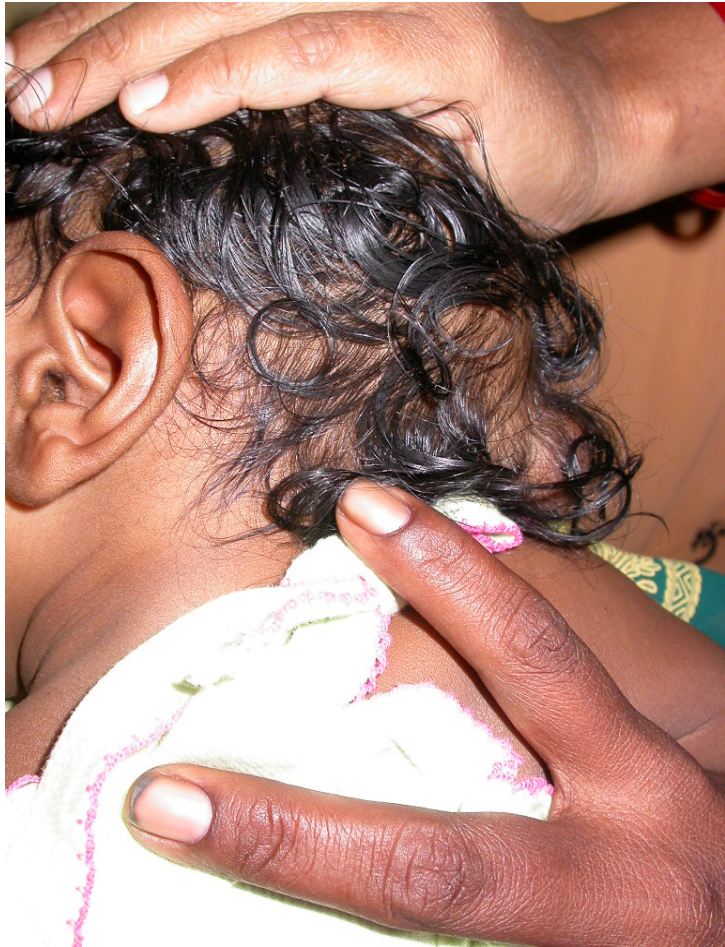

Mongolian Blue spot (no clinical significance - more common in asians)

- **Lumps: abscess, tumour (e.g. sacral lipoma), prominent paravertebral muscle spasm**



**Lipoma**

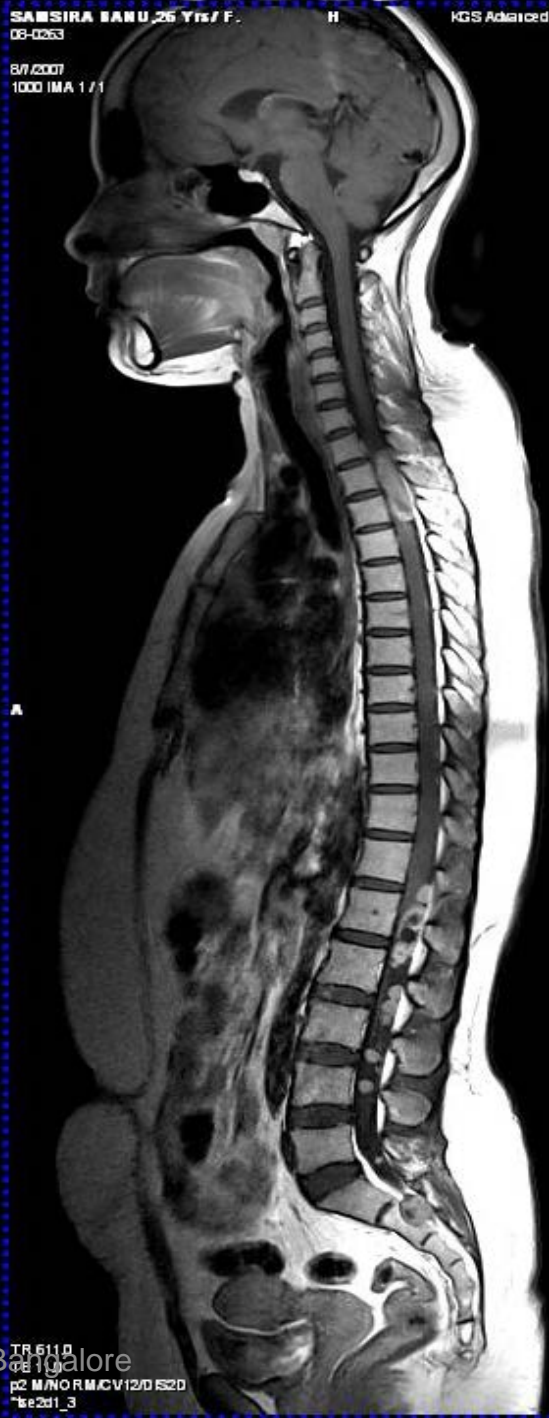
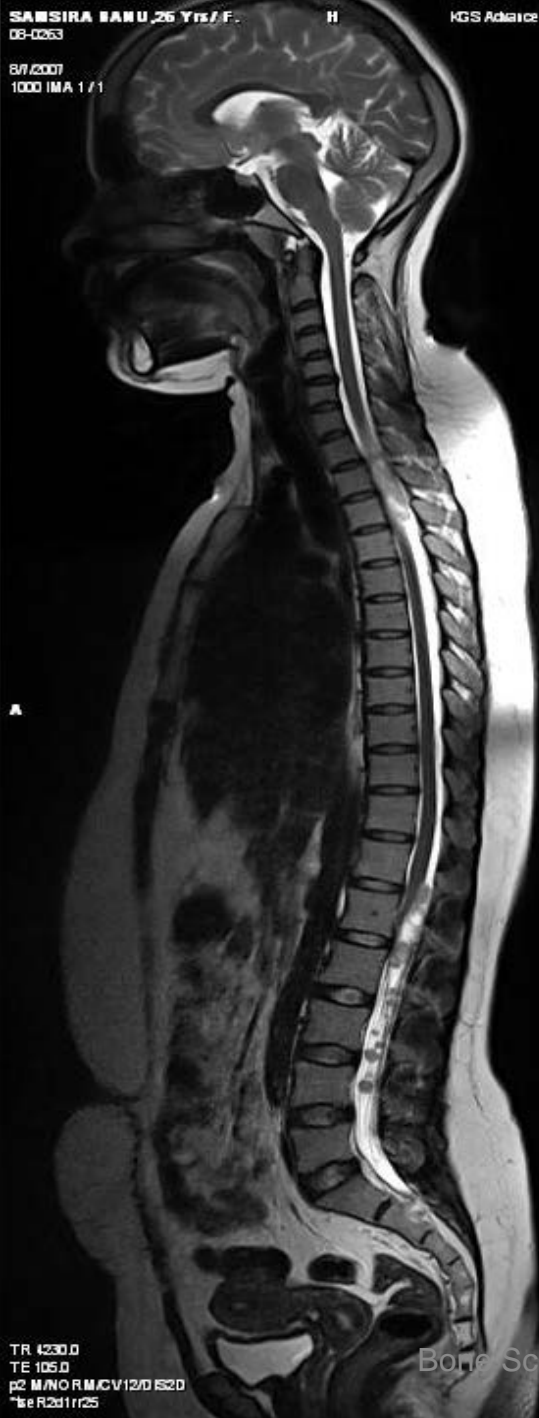
SANSIRA BANU, 26 Yrs / F.  
08-0263  
8/7/2007  
1000 IMA 1 / 1

HGS Advanced MR & CT Scan  
Axi11b  
HFS  
+LPH

SANSIRA BANU, 26 Yrs / F.  
08-0263  
8/7/2007  
1000 IMA 1 / 1

HGS Advanced MR & CT Scan  
Axi11b  
HFS  
+LPH



TR 4230.0  
TE 105.0  
p2 M/NO R/M/CV12/D/IS20  
\*iseR2d11r25

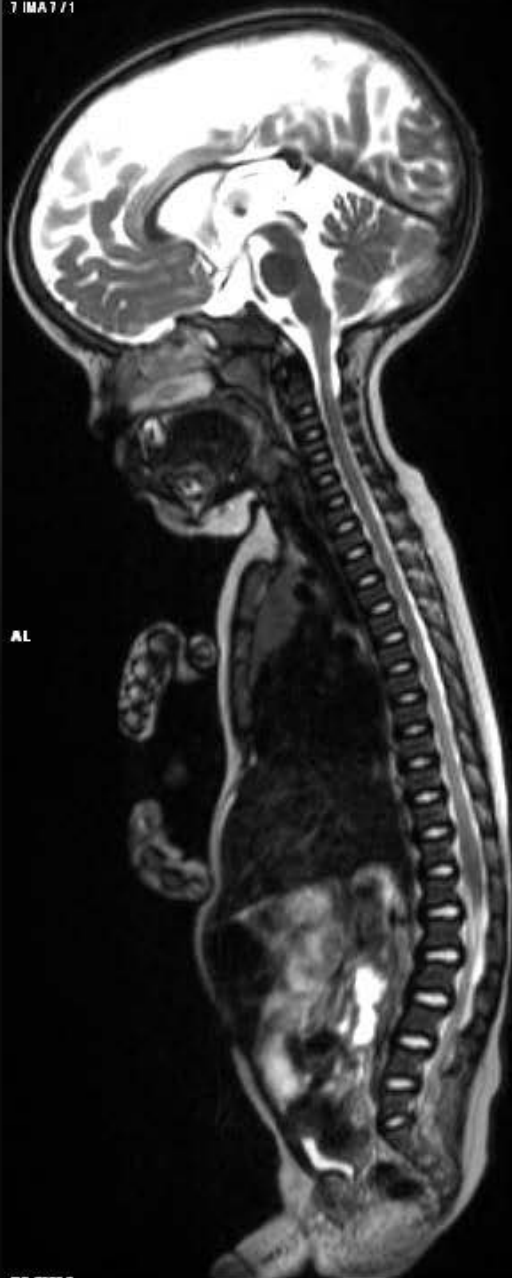Bone School @ Bangalore

TR 511.0  
TE 119.0  
p2 M/NO R/M/CV12/D/IS20  
\*ise2d1\_3

Mias Inapamee S., 2Yrs/F  
07-01063  
7/27/2007  
7 IMA 7 / 1

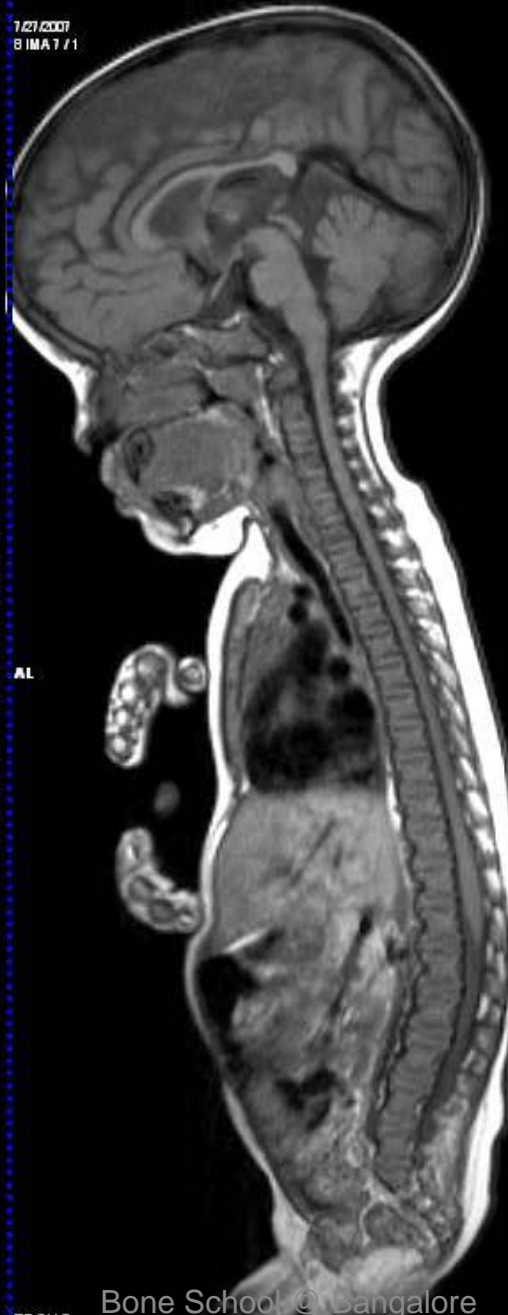HL

KGS Advanced MR & CT Scan  
Ava1/b  
HFS  
+LPH  
7/27/2007  
8 IMA 7 / 1



AL

TR 5360.0  
TE 151.0  
p2 M/ND/NORM



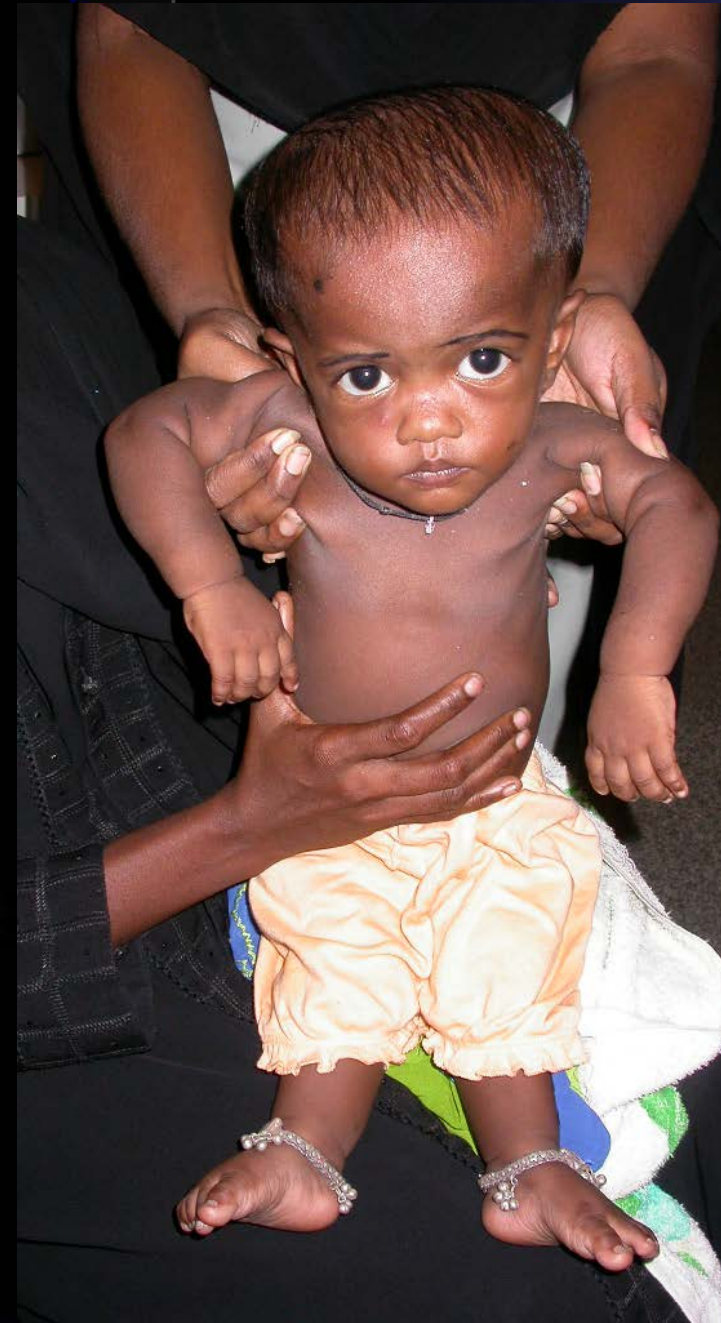AL

TR 611.0  
TE 11.0  
p2 M/ND/NORM

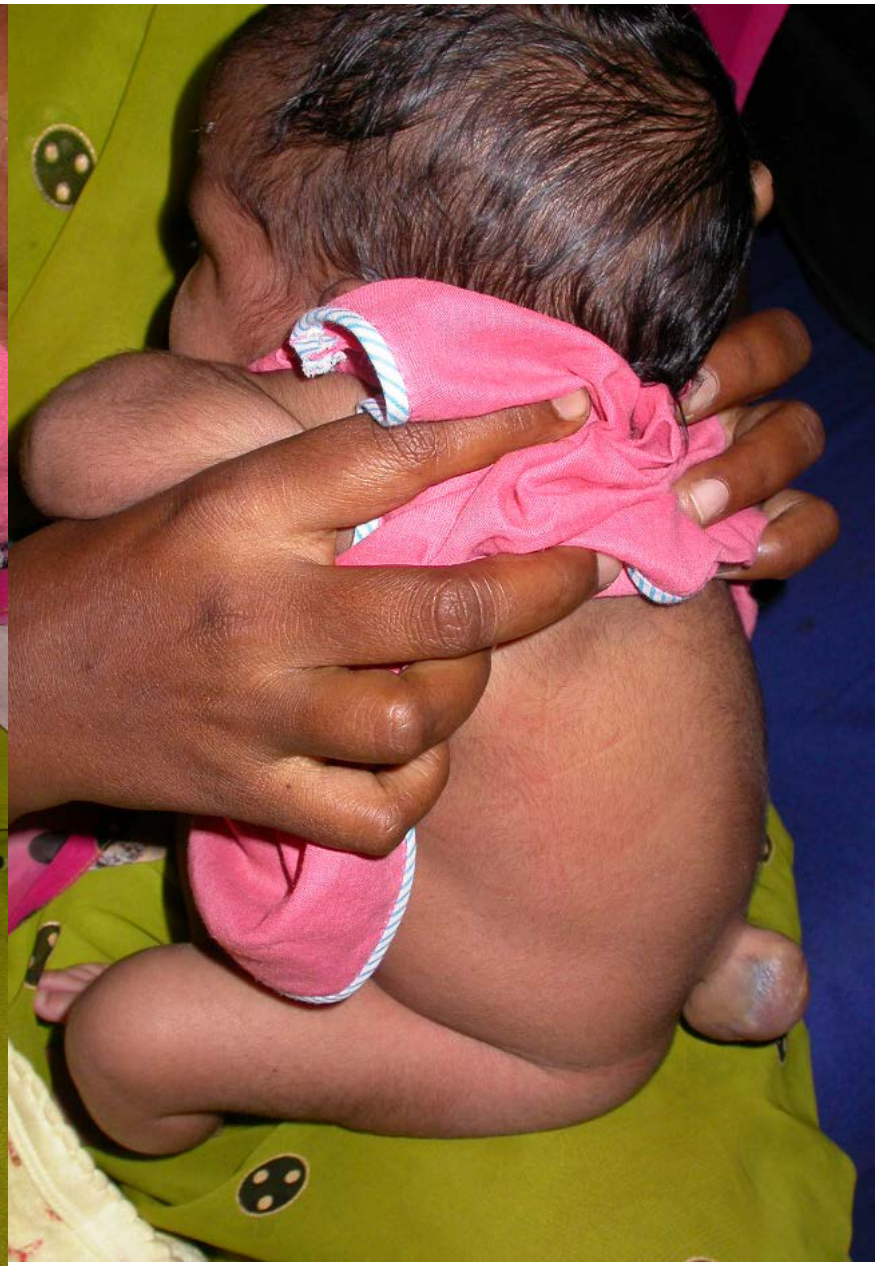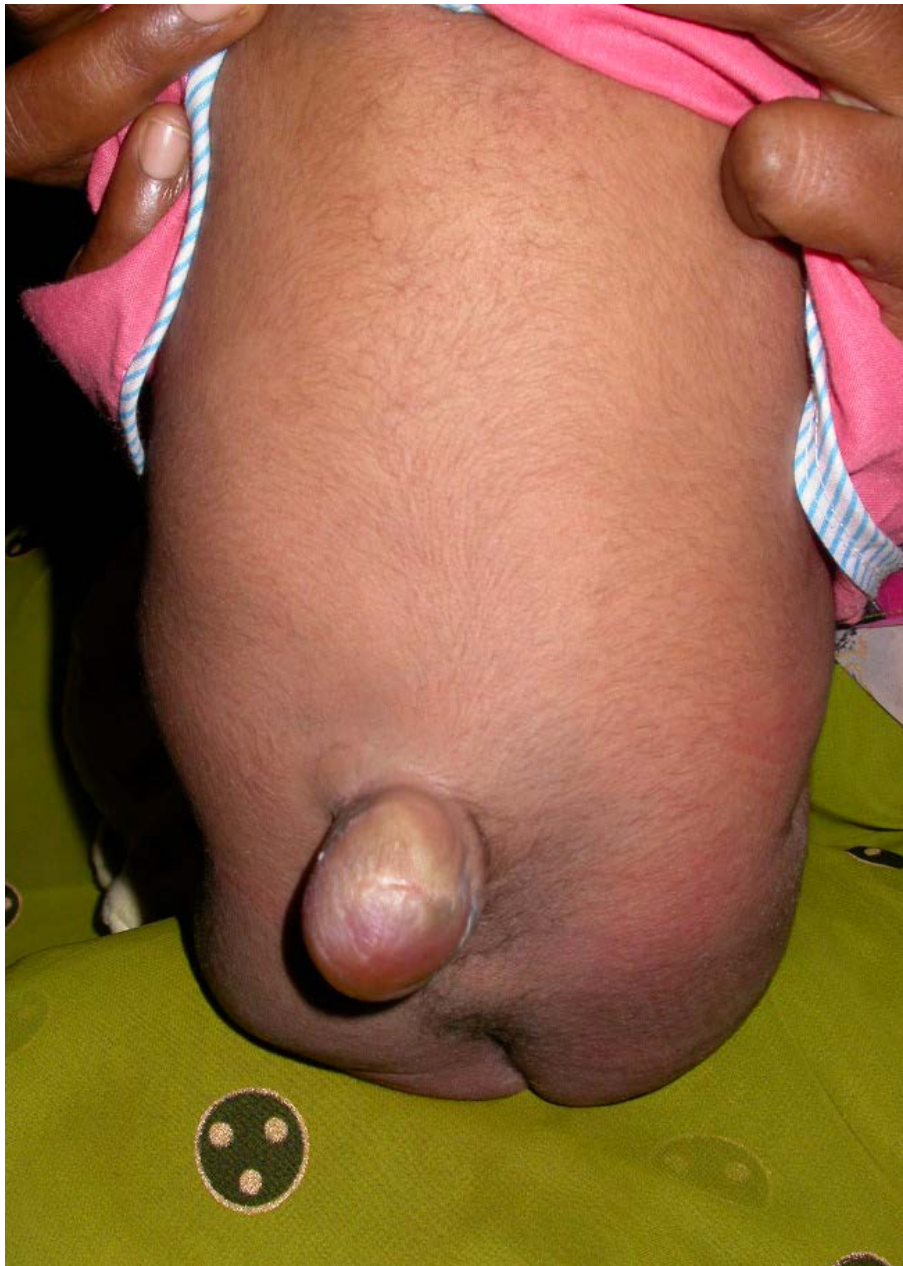Bone School © Bangalore

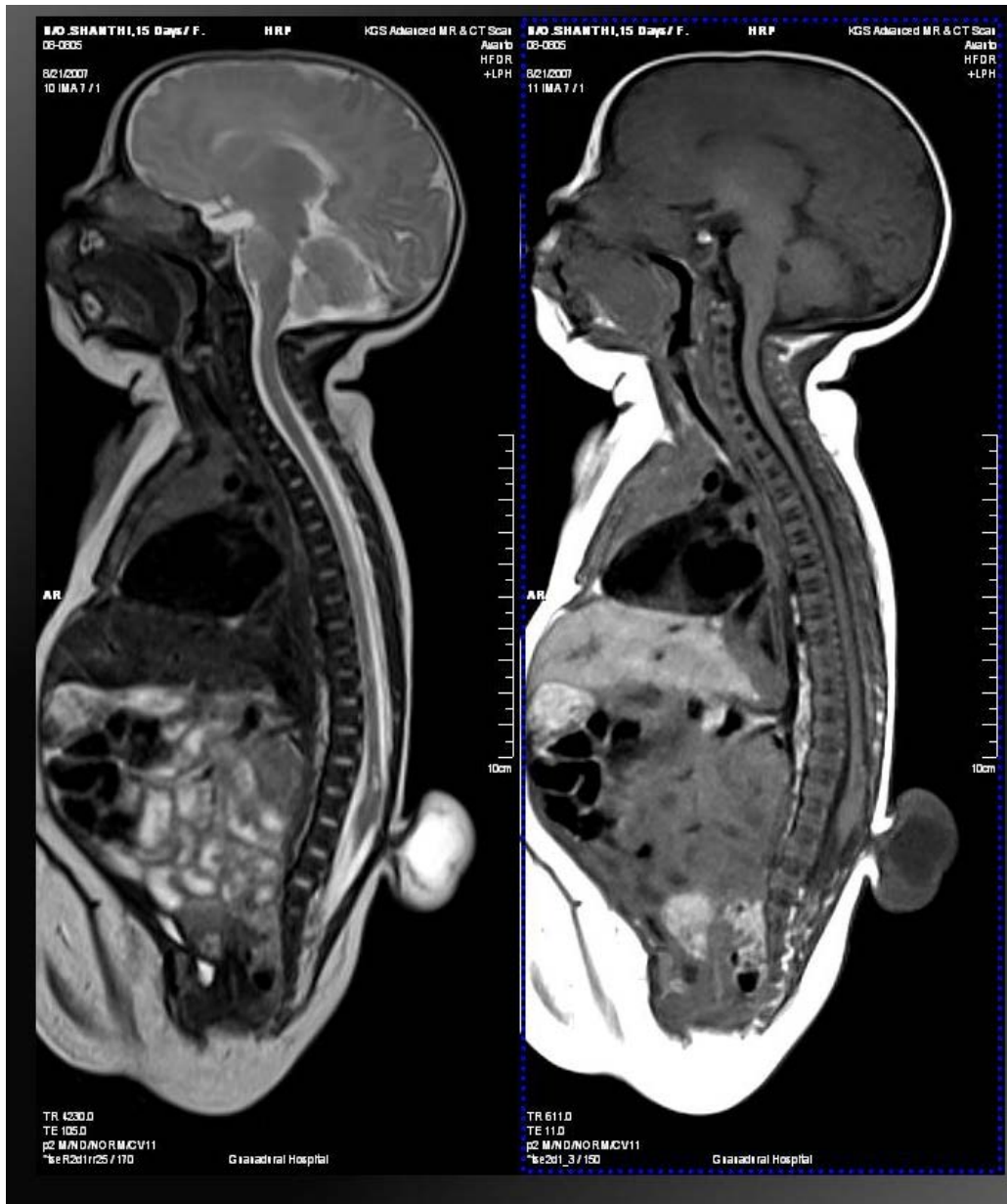HL

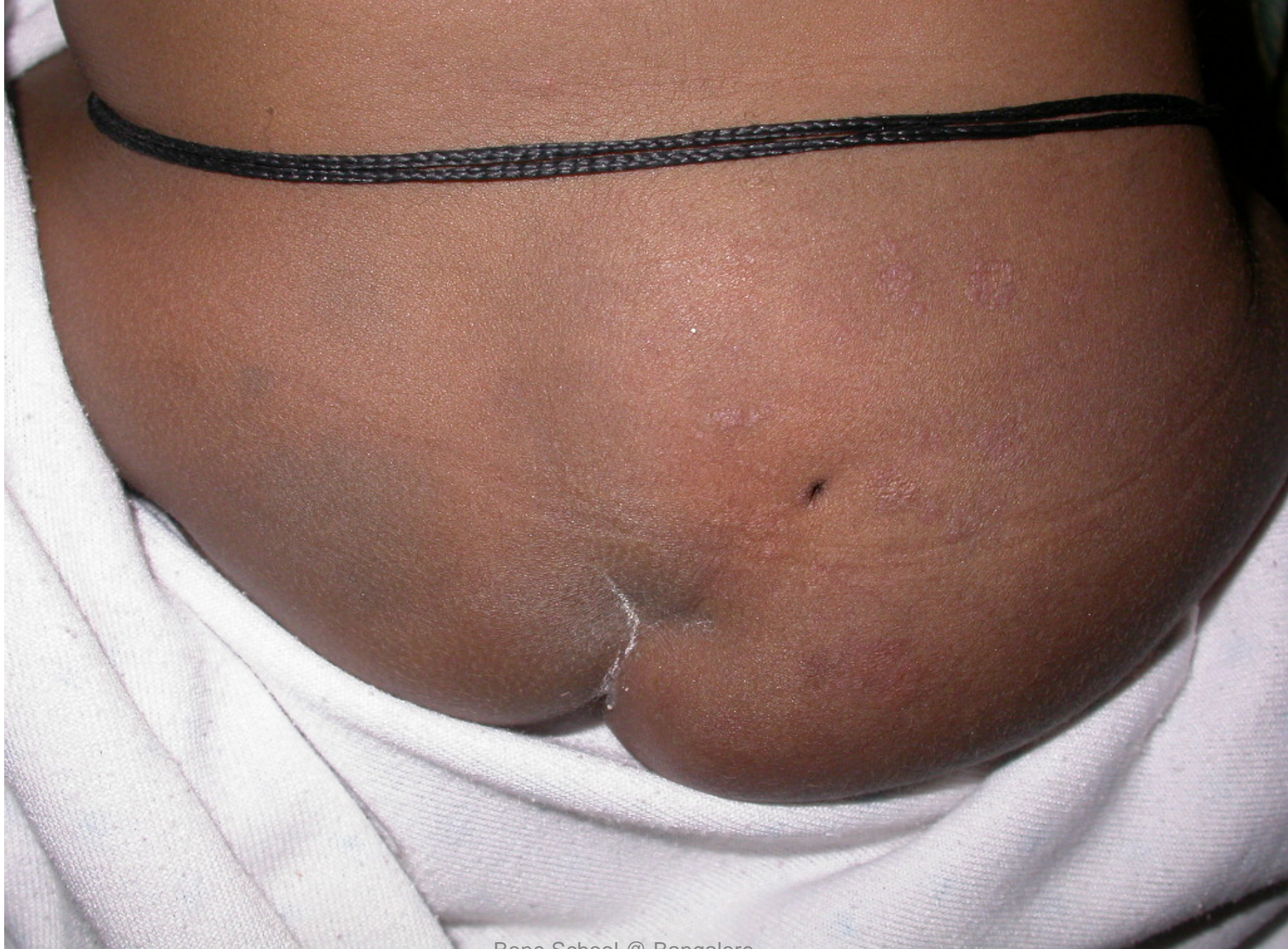KGS Advanced MR & CT Scan  
Ava1/b  
HFS  
+LPH  
7/27/2007  
8 IMA 7 / 1











AL



AL



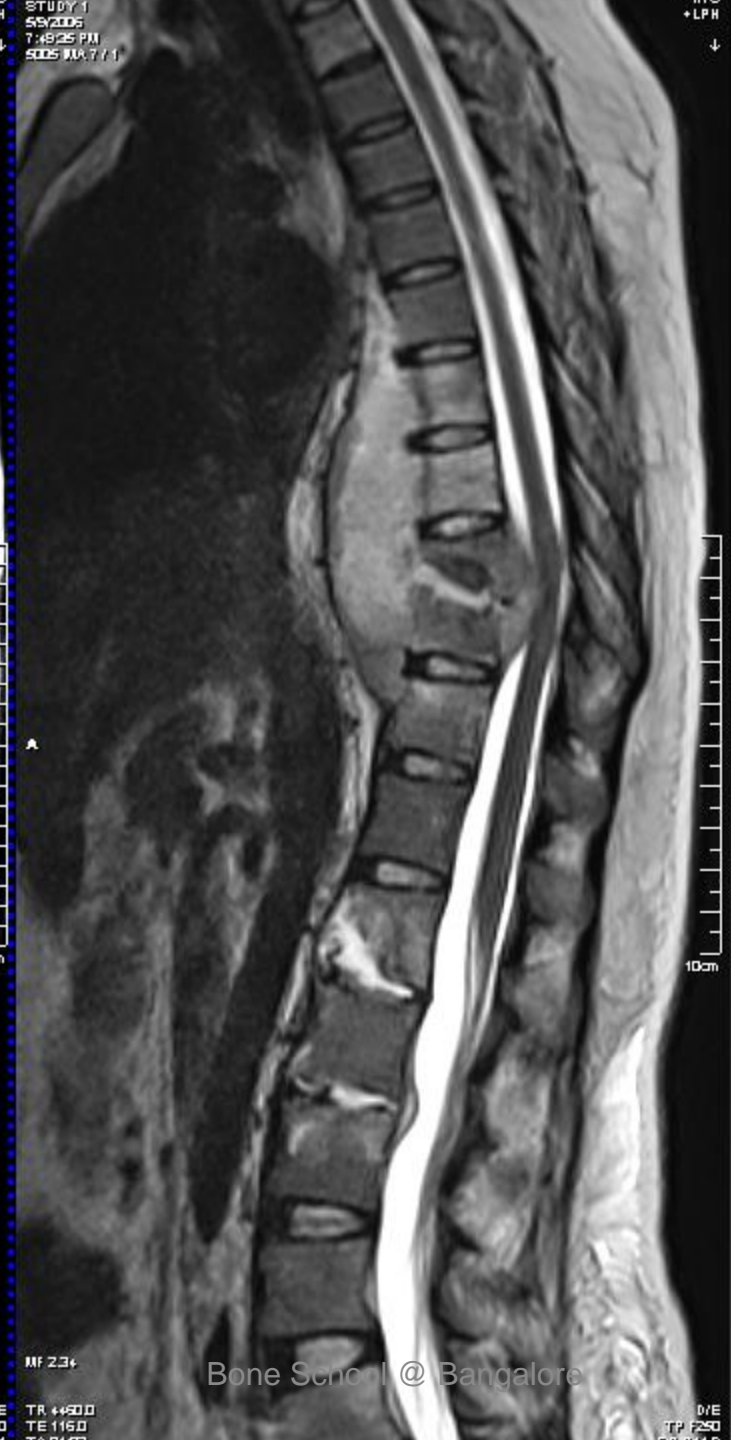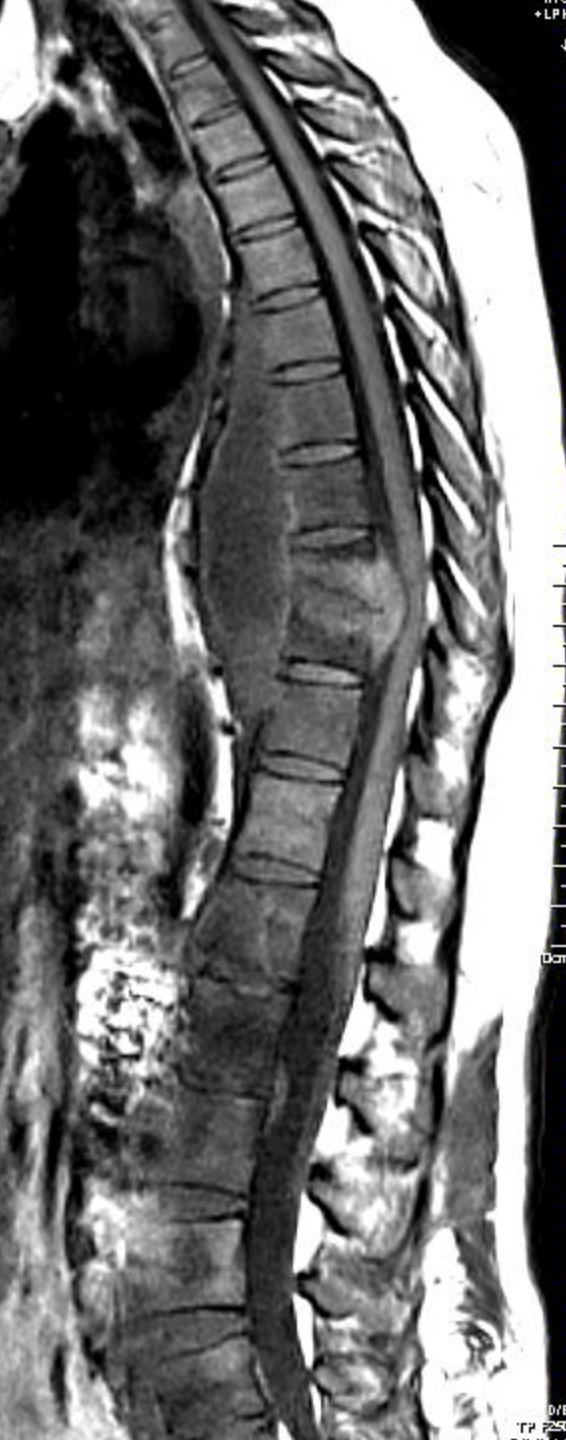1



La



- Spine
  - Kyphosis (exaggerated or reduced)
  - Lumbar lordosis (exaggerated or reduced)
  - Scoliosis (asymmetry of shoulder height / trunk balance / loin crease)
- Round backing / hunched shoulders:  
Schuermann's disease/kyphosis
- Gibbus :
- Any chest deformity



STUDY 1  
5/5/2005  
7:49:25 PM  
5005 MVA 7/7/1

10cm

10cm

MF 236

D/E TR ++800  
TP 250 TE 1160

D/E TR ++800  
TP 250 TE 1160

Bone School @ Bangalore

1

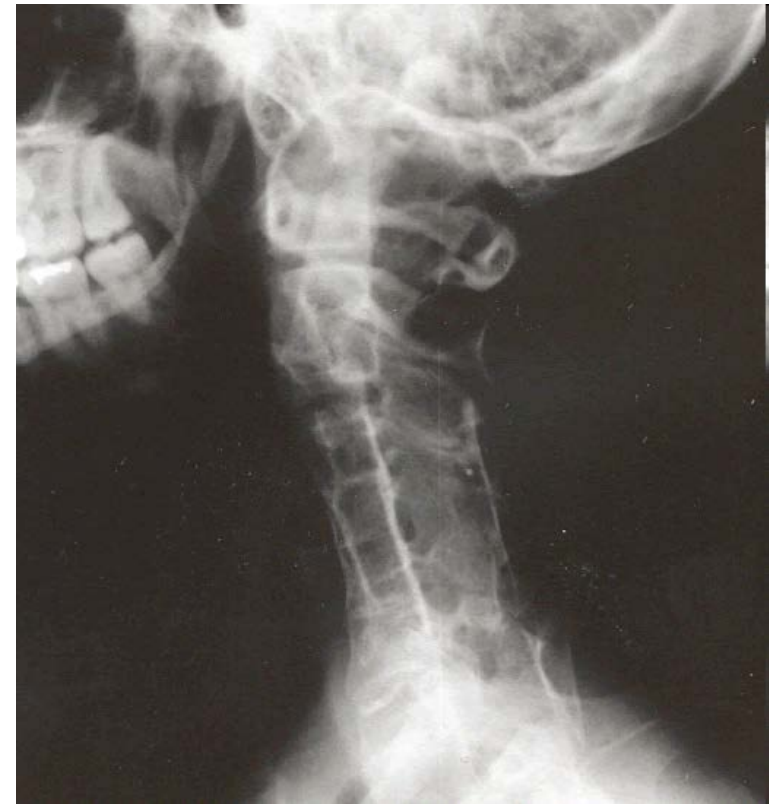
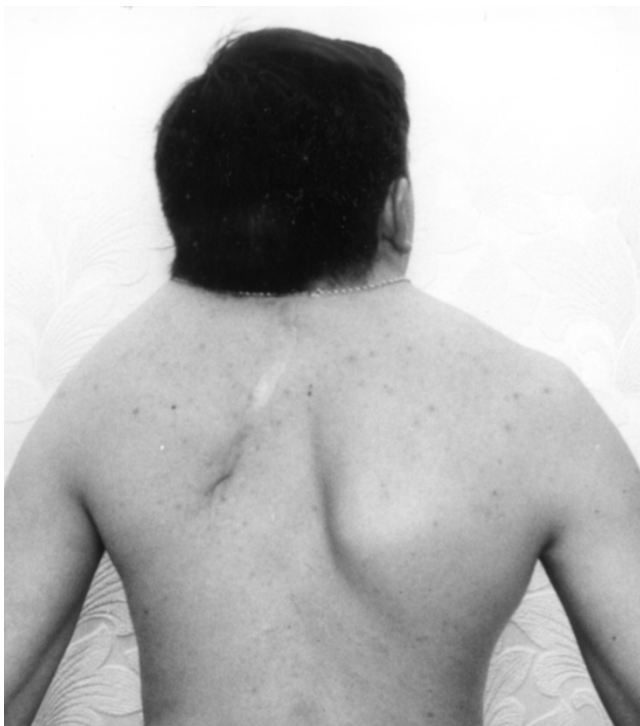
Layout



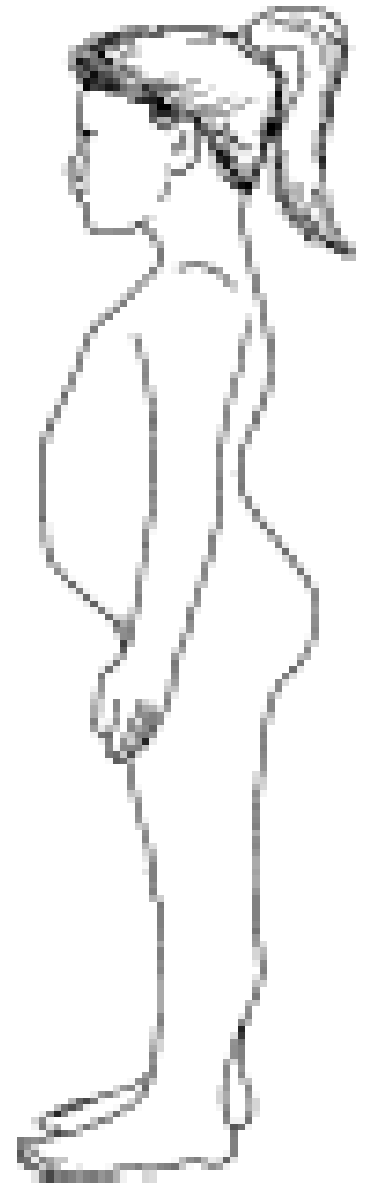# Klippel-Feil syndrome

- Low hairline due to short neck:
- Klippel-Feil syndrome:
- fusion or absence of cervical vertebrae;
- may be associated with Sprengel shoulder (undescended scapula)



## wall test

- The wall test will unmask even small fixed flexion deformities:
- Ask the patient to stand with the back straight against a wall.
- Observe whether the following are in contact with the wall:
  - Occiput
  - Shoulders
  - Buttocks
  - Heels





## *Patient Walking*

- Observe the gait



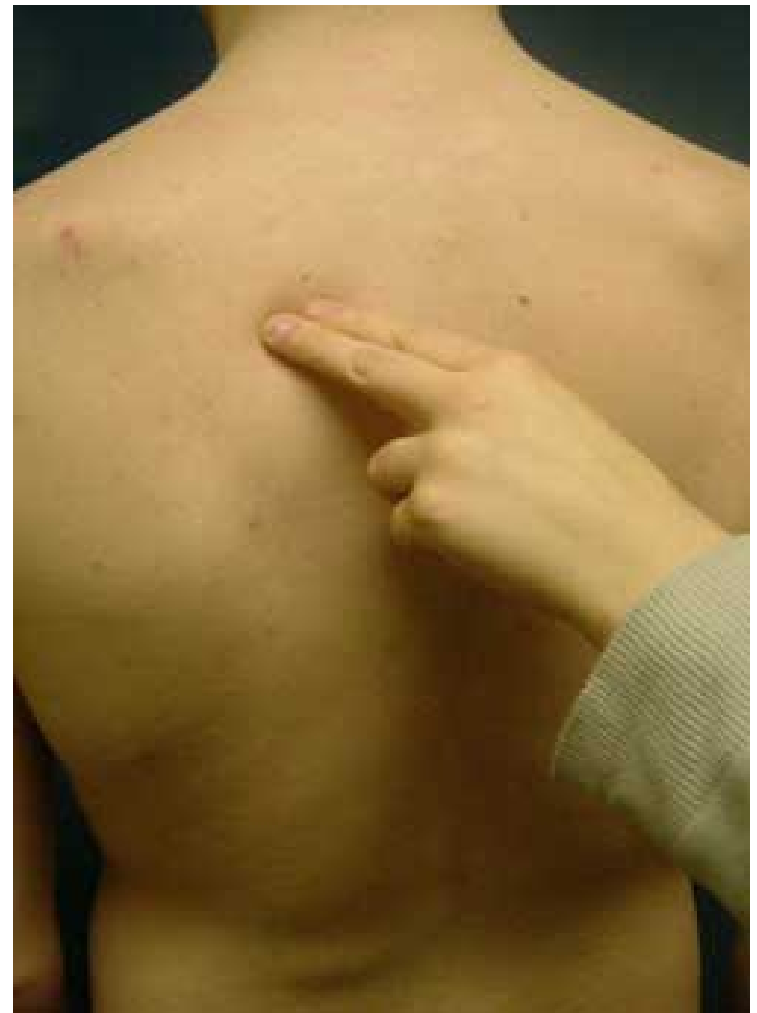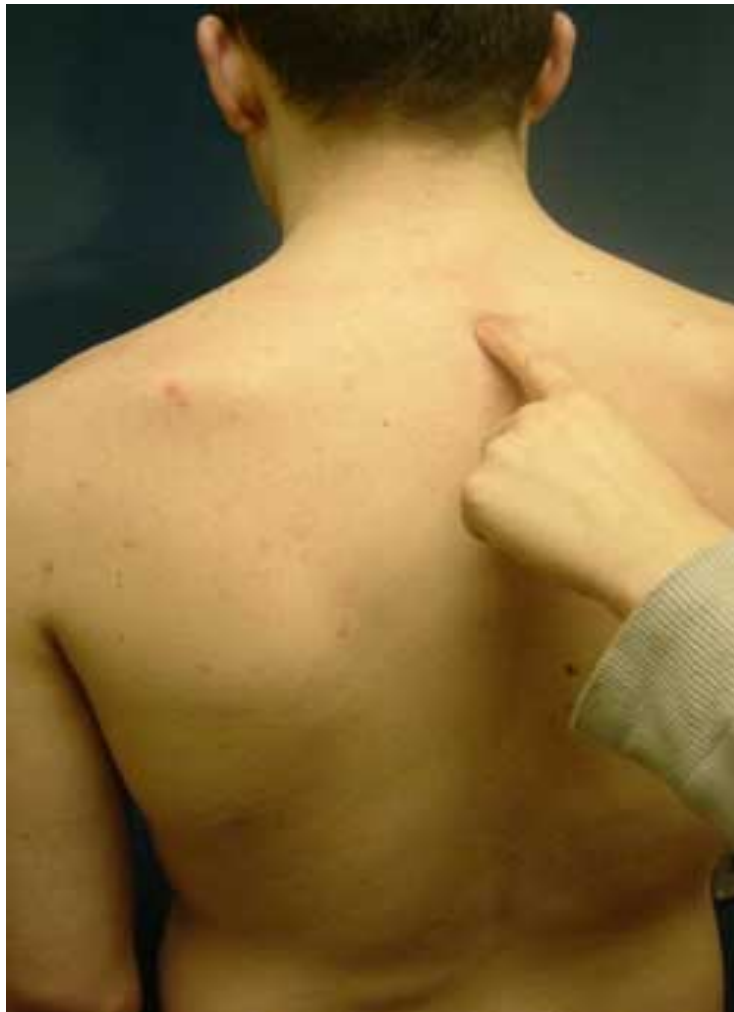# Gait

- Have the patient walk normally then on their toes (tests S1) then on their heels (tests L4/5).
- Observe for abnormal gait patterns including
  - Antalgic
  - Trendelenburg
  - Short leg
  - Foot drop

- **Feel** (sit behind patient)
- Palpate iliac crests bilat, draw line joining them crosses L4-5 disc space.
- Palpate post superior iliac spines, line joining them at lvl of S2
- Palpate between the spinous processes, d lumbosacral jnx n sacroiliac(SI) jnt, paravertebral muscle.
- Look for tenderness, deviatn from vertical alignment, step-off deformity (spondylolithesis), protective muscle spasm
- Gentle percussion – for deeper lesions

# Palpation

- deformity of the spine - steps or a steady contour?



vertebral tenderness - localised or general ?  
paraspinal spasm and muscle tenderness  
sacro-iliac tenderness in sacroilitis

- Elsewhere:
- feel for peripheral pulses
- palpate groin and abdomen for abscesses
- Chest, abdominal, rectal examination

# Move

- Adam's Flexion test – attempt to touch toes. Note any asymmetry of ribcage n lumbar paravertebral area (rib hump and lumbar pillow) in scoliosis, rhythm n any pain in motion.

- Schober's method (measures spinal excursion).
- Extension – ask patient to arch back, support pelvis with your hands. Pain in PID n spondylolysis.
- Lateral flexion – slide hand down each side.
- Rotation – patient seated, twist ard on each side with arms folded. (movement almost entirely



# Movts and measurements

- Measurement of mobility of the spine
- Movements
- Chest expansion
- costovertebral movements are gauged by asking the patient to breathe in and out: the distance between maximal inspiration and expiration is normally 5cm.

# Measurement of mobility of the spine

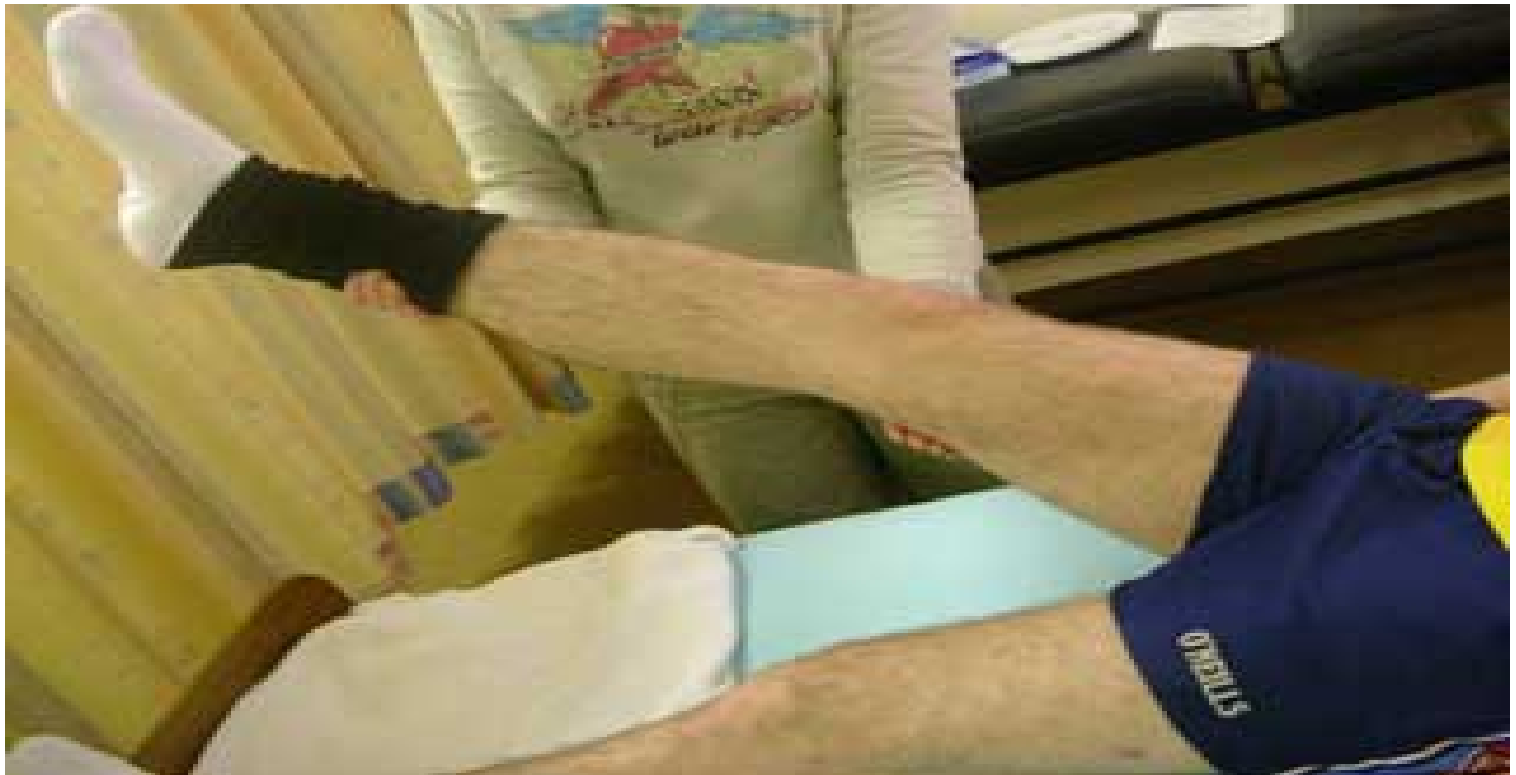- Mark 2 points, one in T1 and another in L1.  
ask the patient to the extent possible.  
Normally there is an increase by 8 cm.
- Mark 2 points, one in L1 and another in S1.  
ask the patient to bend to the extent possible. Normally there is an increase by 8 to 10 cm.

# Neurological examination

- the patient is then asked to lie supine and the straight leg raise test is performed.
- carry out neurological testing of power;
- sensation -
- reflexes -
- do a rectal examination - check tone, power, sensation

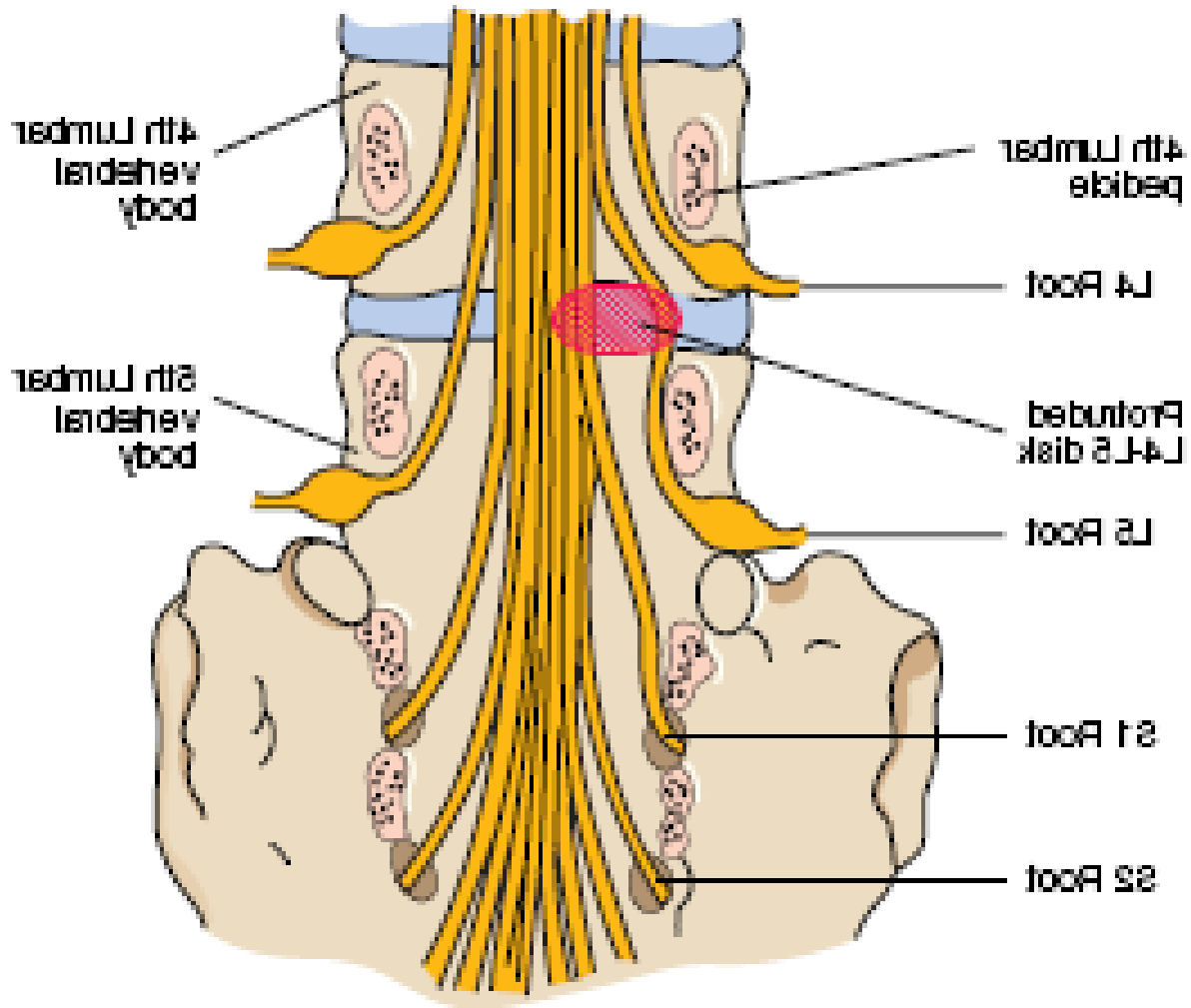
# Straight Leg Raising Test (SLR)

- This is a test for lumbosacral nerve root irritation for example, due to disc prolapse.



- With the patient laid on their back:
- raise one leg - knee absolutely straight - until pain is experienced in the thigh, buttock and calf.
- record angle at which pain occurs - a normal value would be 80-90 degrees - higher in people with ligament laxity
- perform sciatic stretch test - dorsiflex foot at this point of discomfort - test is positive if additional pain results.

- A typical positive SLR is one that reproduces the patient's sciatica between 30 and 60 degrees.



- When the limit of SLR is reached, dorsiflexion of the ankle produces acute accentuation of pain.



- straight leg raising, by itself, can produce pain from a variety of sources, including myogenic pain, ischial bursitis, annular tear, and hamstring tightness, as well as herniated disc
- Pain upon straight leg raising before the leg is raised 30 degrees cannot be due to disc prolapse as the nerve root is not stretched within this range.
- Another explanation of nerve root irritation must then be sought.



# Bowstring Sign

- sciatic stretch test
- performed after a straight leg raising test by lowering the affecting leg a few degrees below the point
- popliteal compression:
- applying compression to the popliteal fossa tensions the sciatic nerve and should provoke symptoms with a lesser degree of a SLR (removing hamstring irritation as a cause of symptoms)

# Crossed SLR

- Crossed SLR - Severe root irritation is indicated when straight raising of the leg on the unaffected side produces pain on the affected side.
- SLR is sensitive, but unspecific, whereas crossed SLR is very specific, but its sensitivity is low (Hakelius & Hindmarsh 1972, Spangfort 1972).

- Straight leg raising has a sensitivity of 91%
- its specificity is only 32%
- it is useful in “ruling out” disc herniation when it is absent.
- If present, crossed straight leg raising is specific (98%, but is not very sensitive (32%)
- Therefore, it is useful to confirm (“rule in”) disc herniation, but its absence is not meaningful.

# Maneuvers

- Seated SLR
  - Seat patient at edge of bed (leg 90 degrees flexed)
  - Extend leg at knee without raising leg off table
  - If patient arches back with both arms extended and has pain below knee, this indicates sciatic involvement
  - Examiner can correlate results of both supine and seated SLR (they should correlate if patient has real nerve root involvement)

# How to assess for malingering - Reverse sciatic tension test

- performed by plantar flexing rather than dorsiflexing the foot
- if this results in increased complaints of pain, then pt is malingerer

# How to assess for Malingering

- Hoover test (assesses true leg weakness)
  - Patient lies supine
  - Examiner cups hands under heels of patient
  - Ask patient to raise the weak leg off table
  - If no downward pressure is felt from unaffected leg as patient lifts affected leg, then patient is not giving a full effort

# How to assess for Malingering

- Waddell's Signs
  - Superficial, non-anatomic tenderness (pinching or stroking skin replicates back pain)
  - Axial loading (pressure on top of head) replicates low back pain
  - Distraction – difference between SLR and seated SLR
  - Non-physiologic pain patterns (doesn't follow nerve roots)
  - Voluntary release during strength testing

# Maneuvers

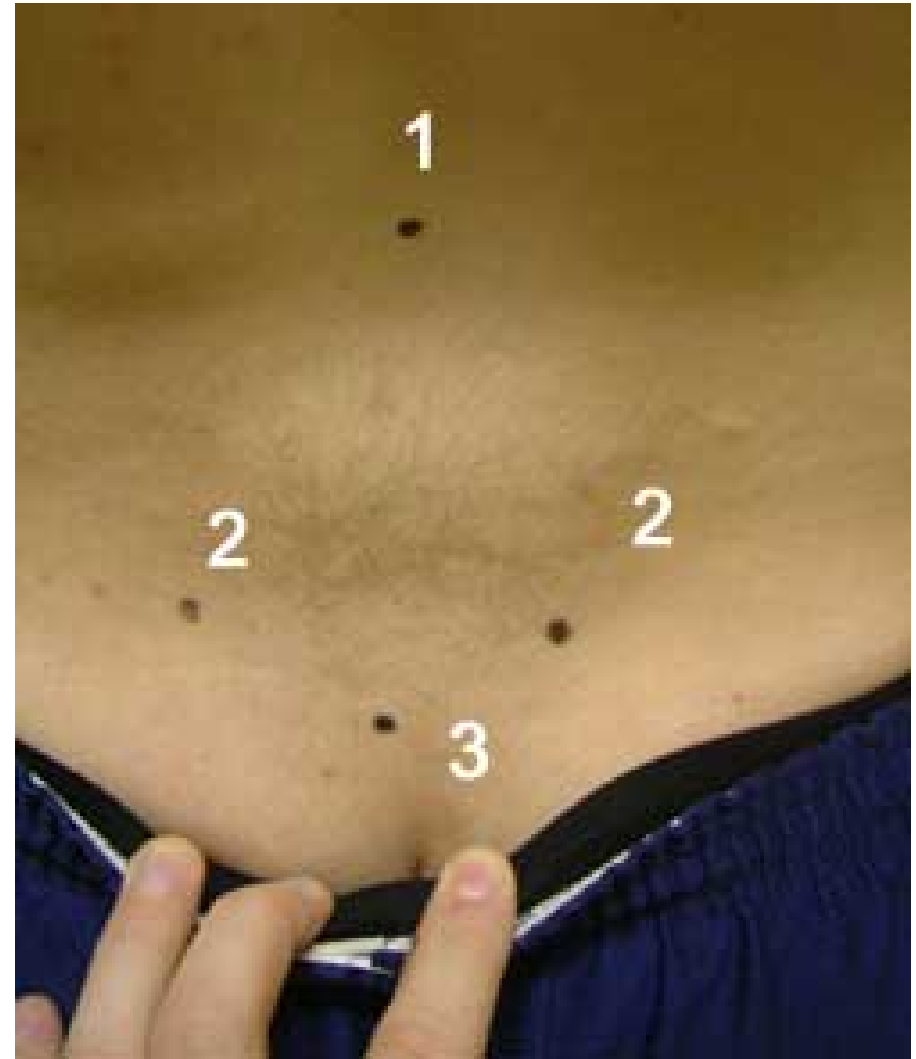
- FAIR position (for Piriformis Syndrome)
  - Place patient on side
  - Flex, Adduct, Internally Rotate affected leg
  - This position stretches the piriformis muscle maximally which would irritate sciatic nerve if patient has piriformis syndrome



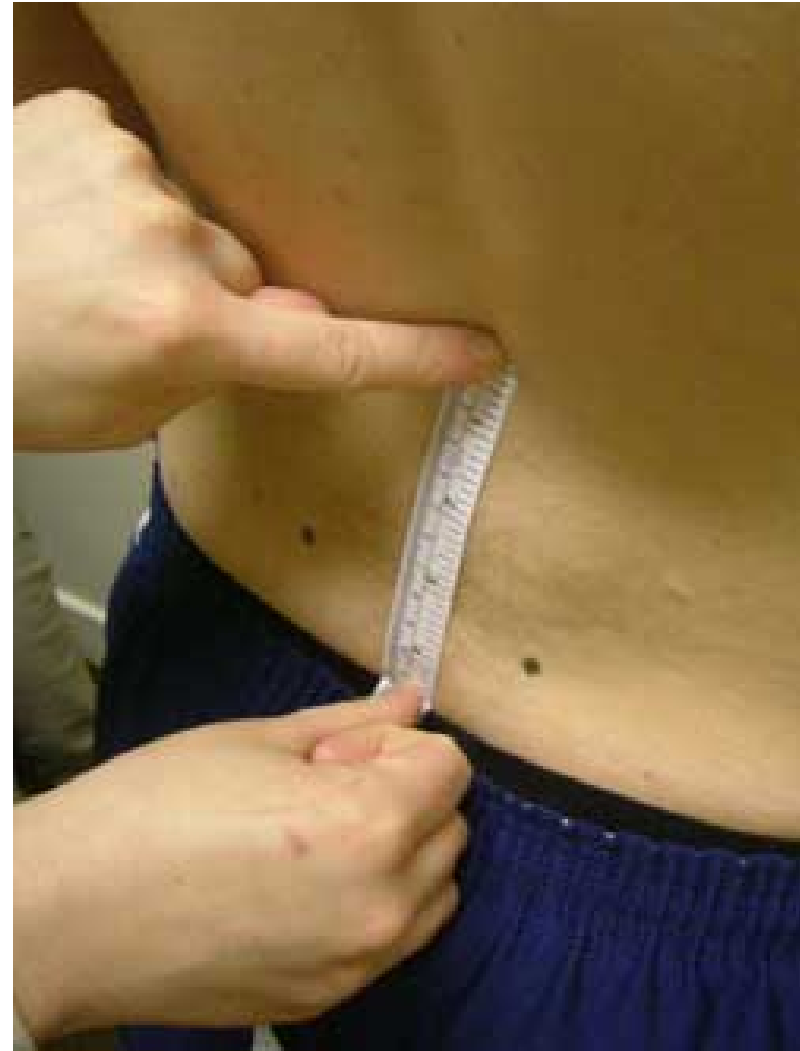# Schober's test

- Schober's test assesses the amount of lumbar flexion.
- In lumbar spine flexion, hip flexion can compensate to a considerable extent for a loss of spinal flexion.
- Schober's test done to objectively measure the degree of spinal flexion.

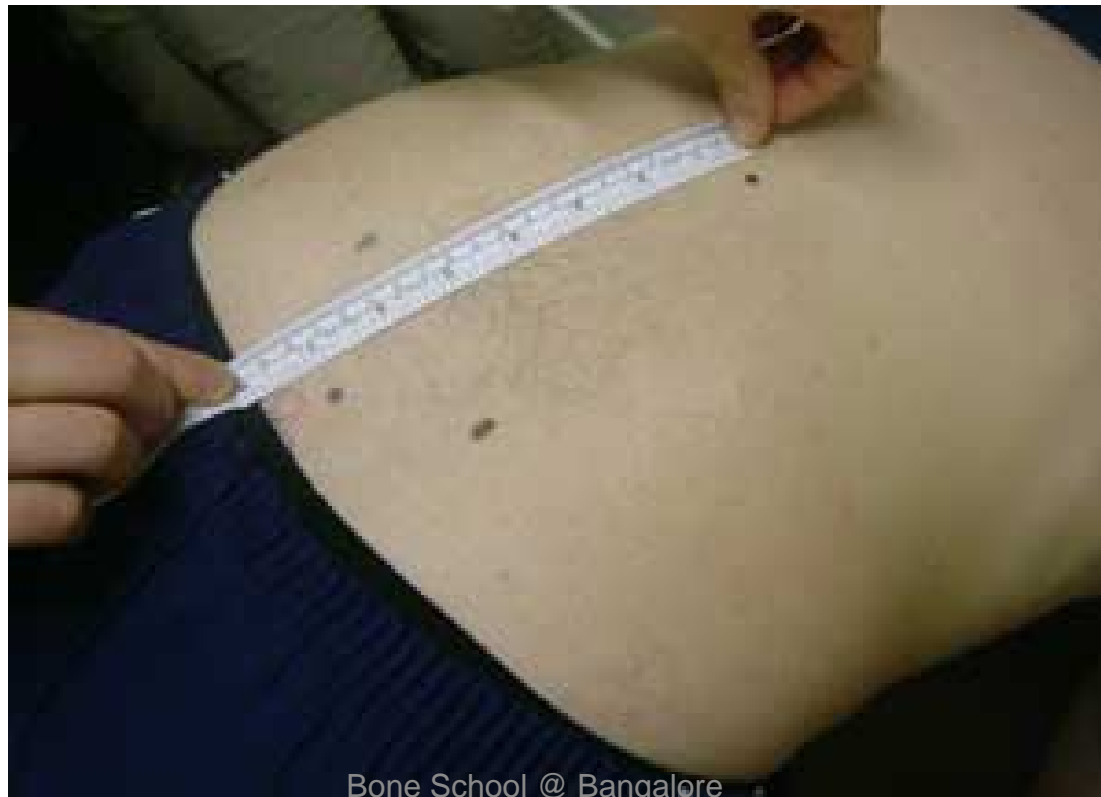- Firstly identify the Dimples of Venus.
- Now in the midline, use a tape measure and pen to mark a point 10cm superior to, and an other mark 5 cm inferior to this point.



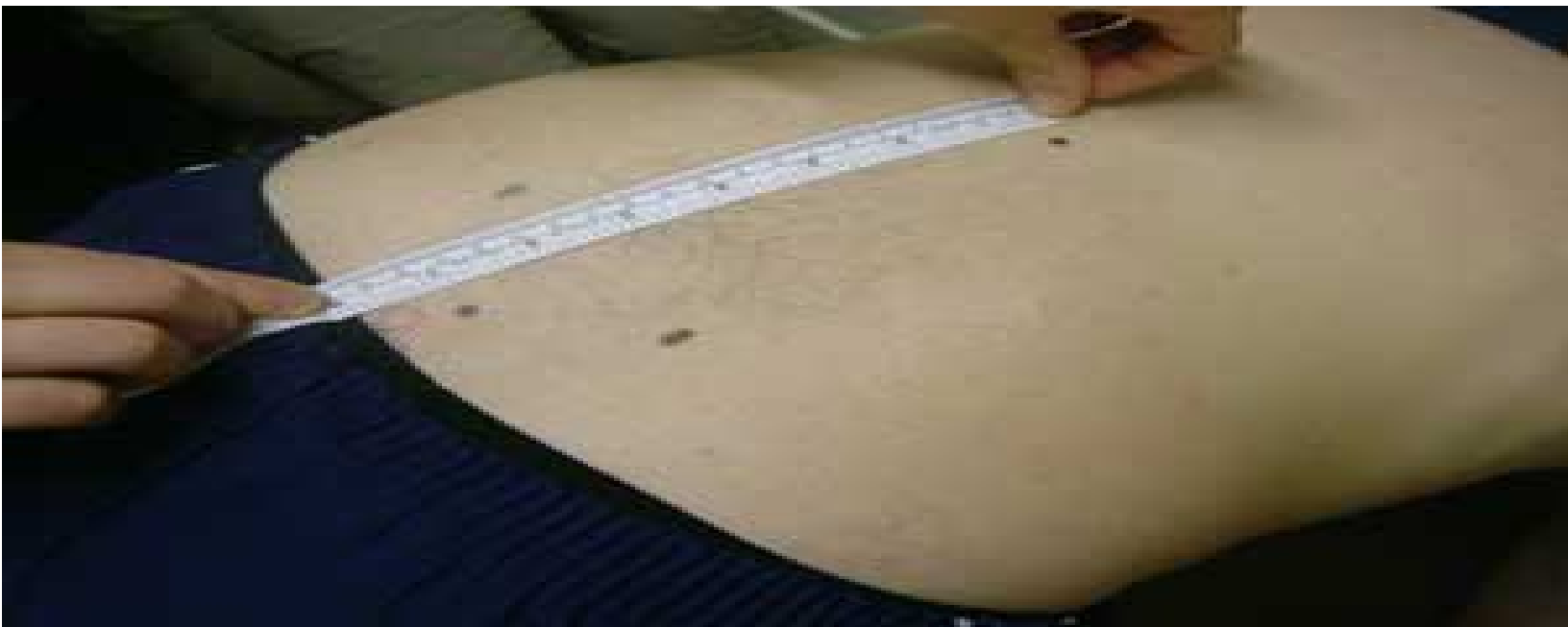- a mark is made at the level of the posterior iliac spine on the vertebral column, i.e. approximately at the level of L5.
- The examiner then places one mark 5cm below this mark and another about 10cm above this mark.



- Ask the patient to attempt to “touch their toes”.
- The distance between these two marks should be measured when the patient’s spine is flexed maximally.



- The distance should increase to more than 21cm in a normal patient.



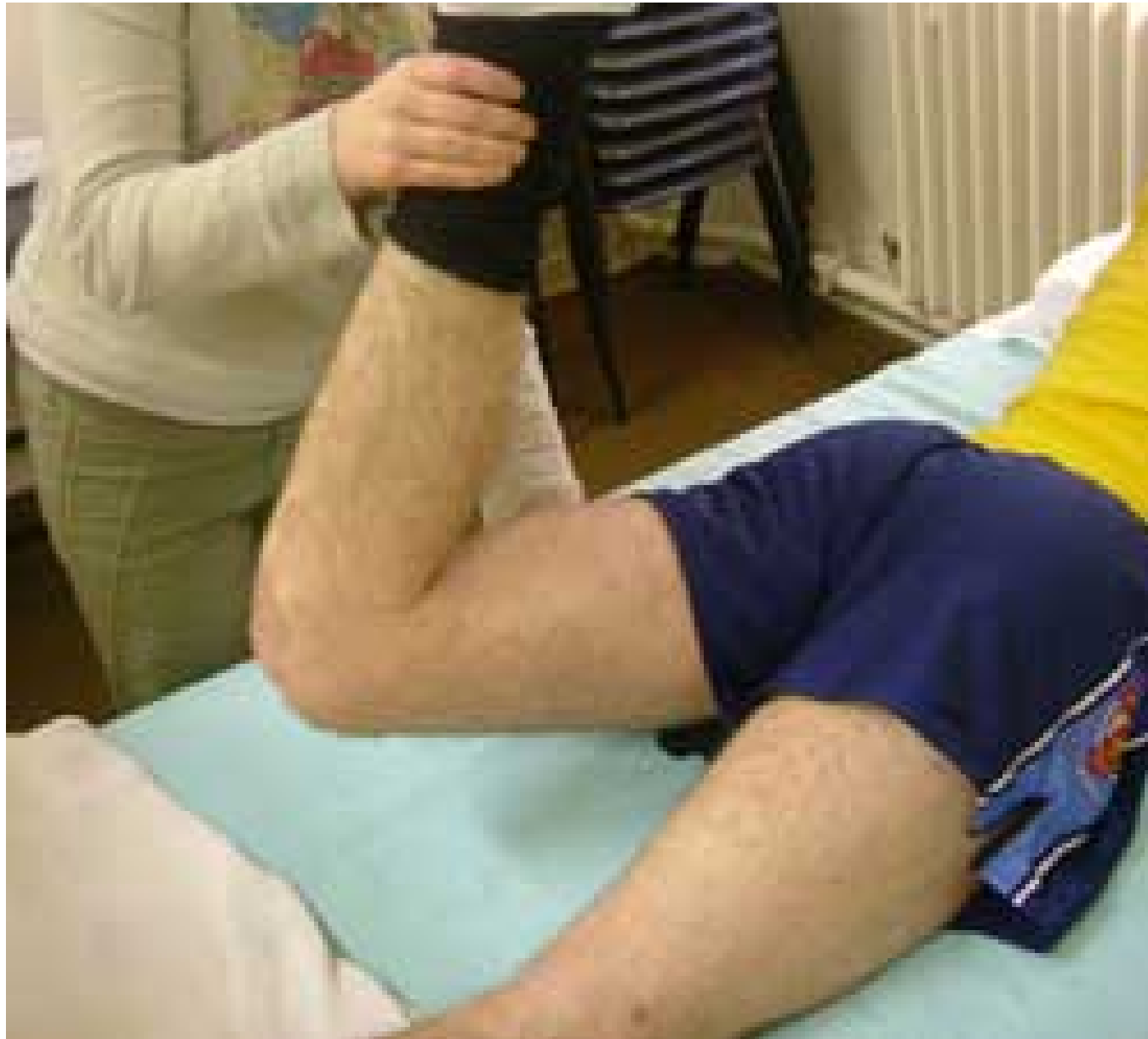- A modified way to demonstrate lumbar spine flexion is to place several fingers over the lower lumbar spinous processes and ask the patient to bend forward and touch their toes as best as possible.
- In a normal spine your fingers should move part.

- If the increase in distance between the two fingers on the patients spine is less than 5cm then this is indicative of a limitation of lumbar flexion.
- This test allows serial measurements for patients with progressive disease to be undertaken.

# Femoral stretch

- Have the patient lie prone.
- Passively flex the knee as far as it goes. In a positive test the patient should feel pain in the ipsilateral anterior thigh (i.e. the distribution of the femoral nerve)
- Also pain may be exacerbated on hip extension.





Bone School @ Bangalore

# Neurological assessment

- Neurological assessment is an essential part of the examination of the spine.
- The examination should involve a full assessment of muscle wasting, fasciculation, tone, power, coordination / proprioception, sensation and reflexes.
- perianal reflexes and sphincter tone should be tested.

# Cervical Spine Physical Examination

## Surface Anatomy

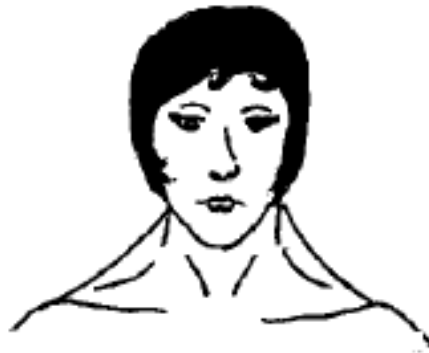- Inspect from posterior aspect
- **Vertebra Prominens** : at the cervicithoracic junction.(spinous process of C7)
- Loss of cervical lordosis : nonspecific reaction to cervical spine pain
- More dramatic reduction: in ankylosing spondylitis

# Inspection of cervical spine

- General observation at rest.
- Look for posture, symmetry (e.g. shoulder height, scapular prominence, waist, pelvis), skin (colour, scars, lesions, creases), muscle wasting, joint swelling.


# Inspection of cervical spine

- Deformity of the cervical spine is unusual.
- Characteristic features may be seen in:
  - cervical spondylosis
  - Klippel-Feil syndrome - congenital short webbed neck with a low hair line



Congenital webbing of the neck  
Bone School @ Bangalore

- acute torticollis
- Instability of the cervical spine may easily be missed in a supine patient.
- Check that the patient can easily support their head.



**Torticollis or 'wryneck' – may be  
secondary to prolapsed disc**

# Inspection

- Observe the muscles for spasm or contracture.
- Contracture of the sternomastoid may be due to spasm, trauma or congenital cause.
- The latter may result in a torticollis, in which the patients holds the neck rotated to the side opposite to the lesion.



# Inspection

- enlarged thyroid gland or lymph nodes may be visible.
- An abscess may point in part of the neck.
- Instability of the cervical spine may easily be missed in a supine patient.
- Check that the patient can easily support their head.

# Palpation

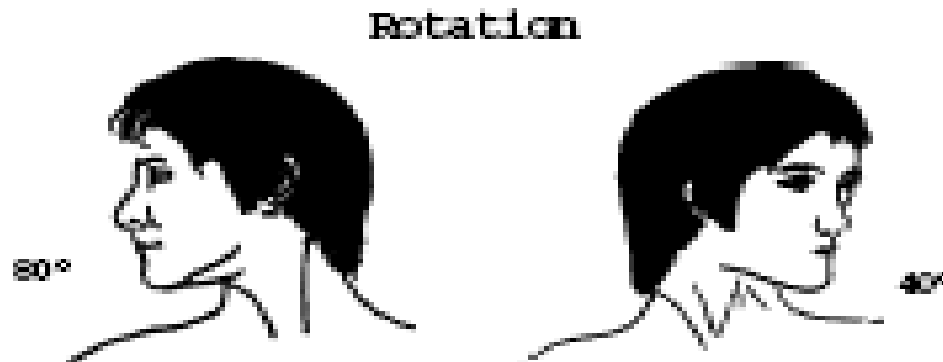
- ▶ Reveal a subtle deformity
- ▶ Detect paraspinal muscle spasm
- ▶ Point tenderness
- ▶ Palpate the spinous process in midline : tenderness in emergency situation indicates spine instability
- ▶ Evaluate alignment, acute lateral shift due to unilateral facet joint dislocation or fracture , increase in space due to posterior ligamentous disruption.
- ▶ Palpate posterior facet joint firmer 2cm lateral to midline
- ▶ Localize trigger points in area superior to spine of scapula and between thoracic spinous process and medial border of scapula

# Range Of Motion

- ▶ The thoracic spine should be supported.
- ▶ Having patient sitting on a straight –back chair extend to midscapular level.
- ▶ Midrange pain due to instability of the structure being moved.(degenerative disk disease)
- ▶ To assess flexion , attempt to touch chin to chest.
- ▶ To assess extension , tilt the head back , looking up the ceiling
- ▶ 50% flexion-extension motion occurs between occiput and C1
- ▶ Lateral rotation: rotate the chin laterally toward each shoulder , in turn, typically 60 degree in each direction ,50% normally occurs between C1 and C2.
- ▶ Lateral bending : attempt to touch each ear to ipsilateral shoulder.

# rotation

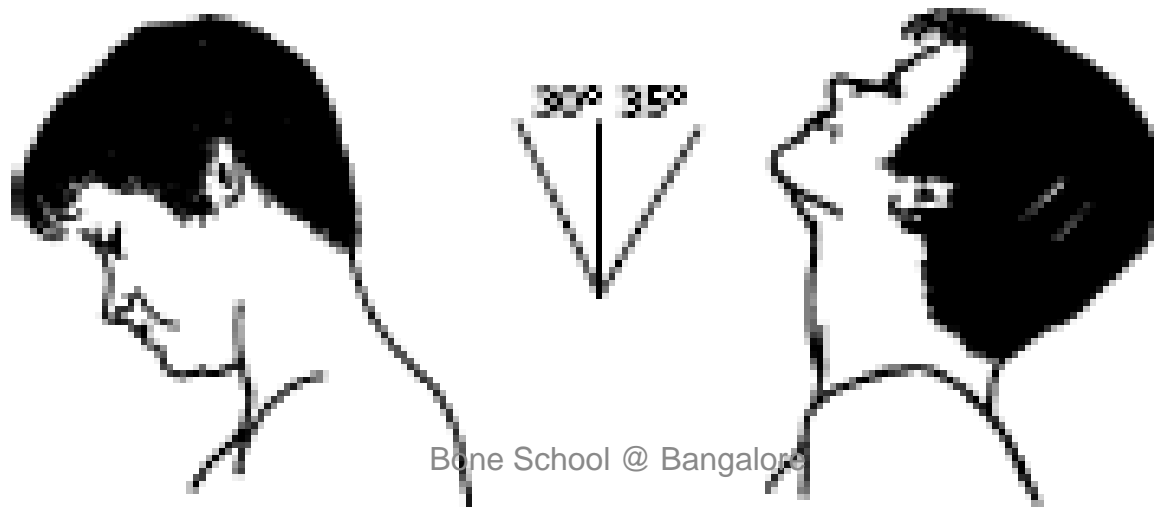
- Should be equal
- About 70-90° to each side.



# Flexion and extension

- Full flexion when chin touches the chest
- Full extension of at least 30\* beyond the horizontal should be possible.
- Usually greater in young people.

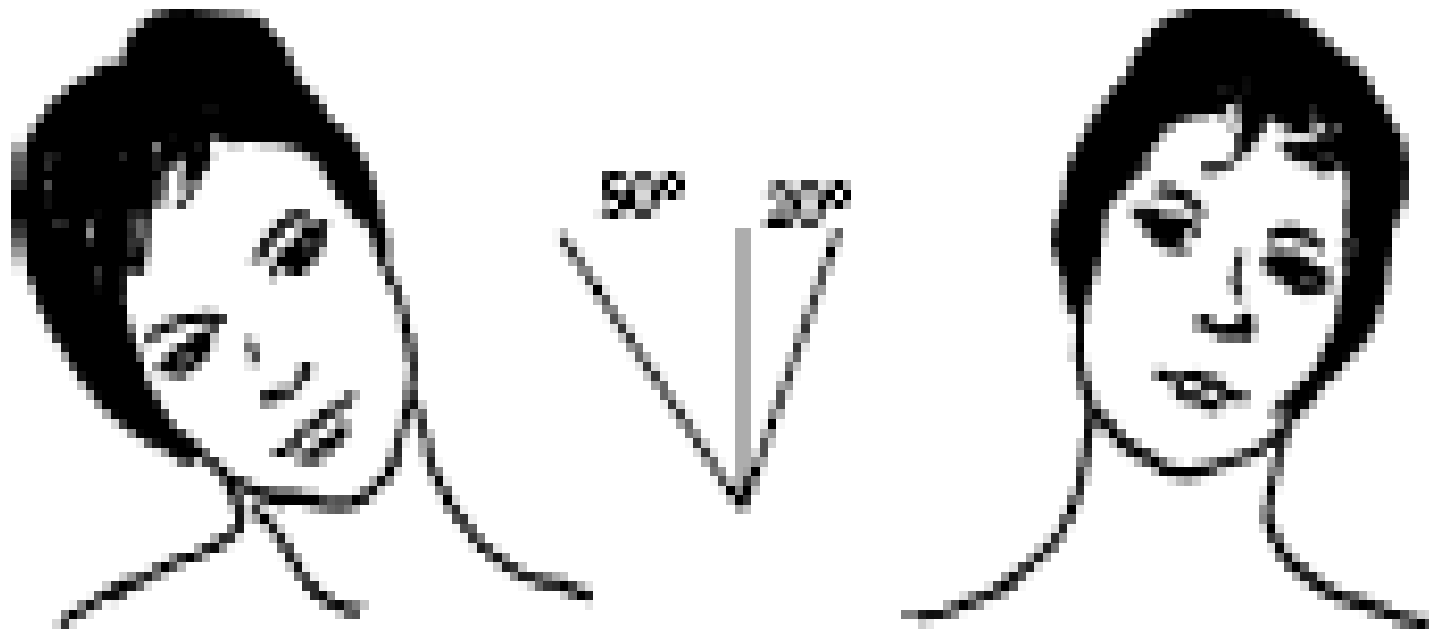
## Flexion and extension

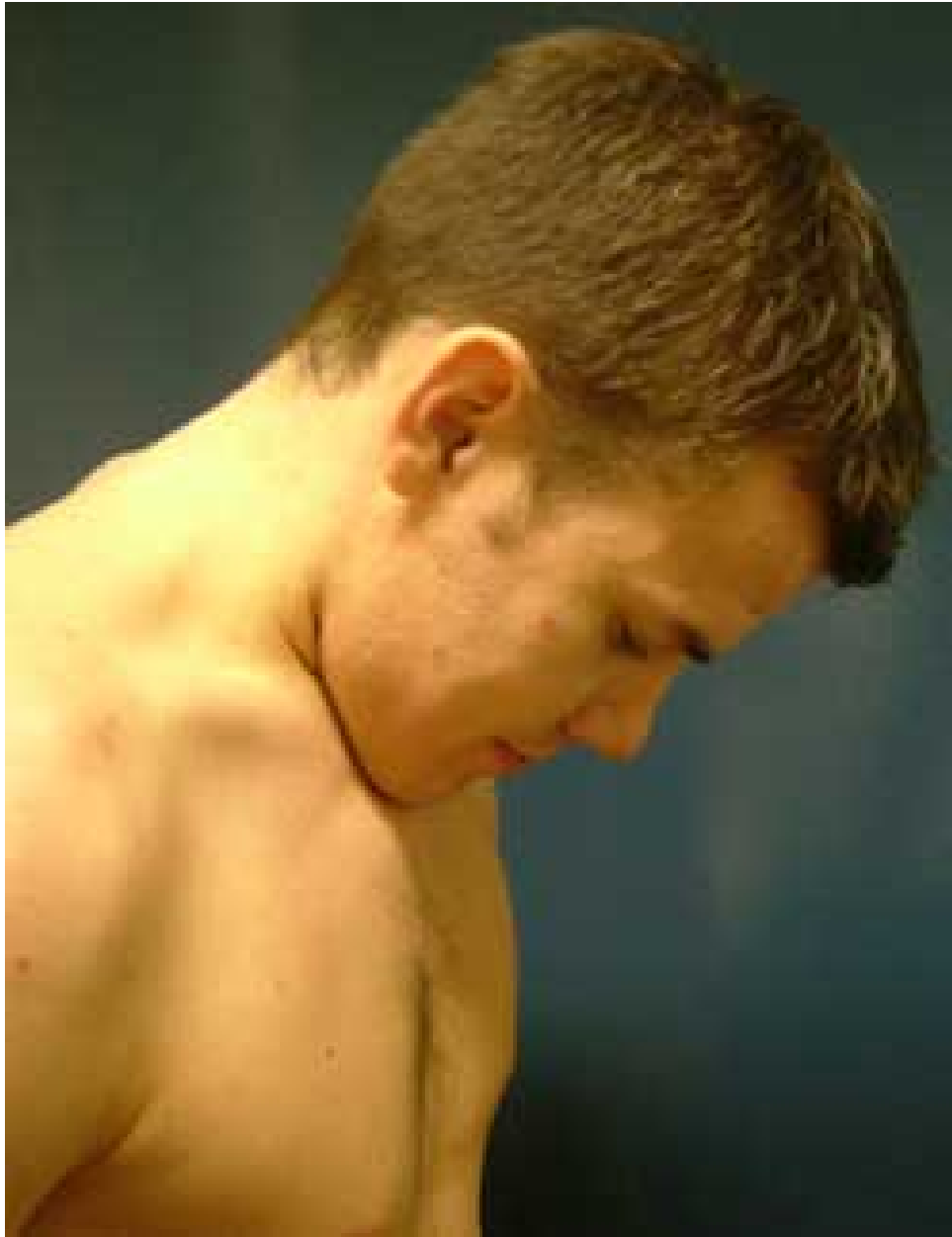

# Lateral flexion

- Atleast 40\* to each side.

## Lateral flexion



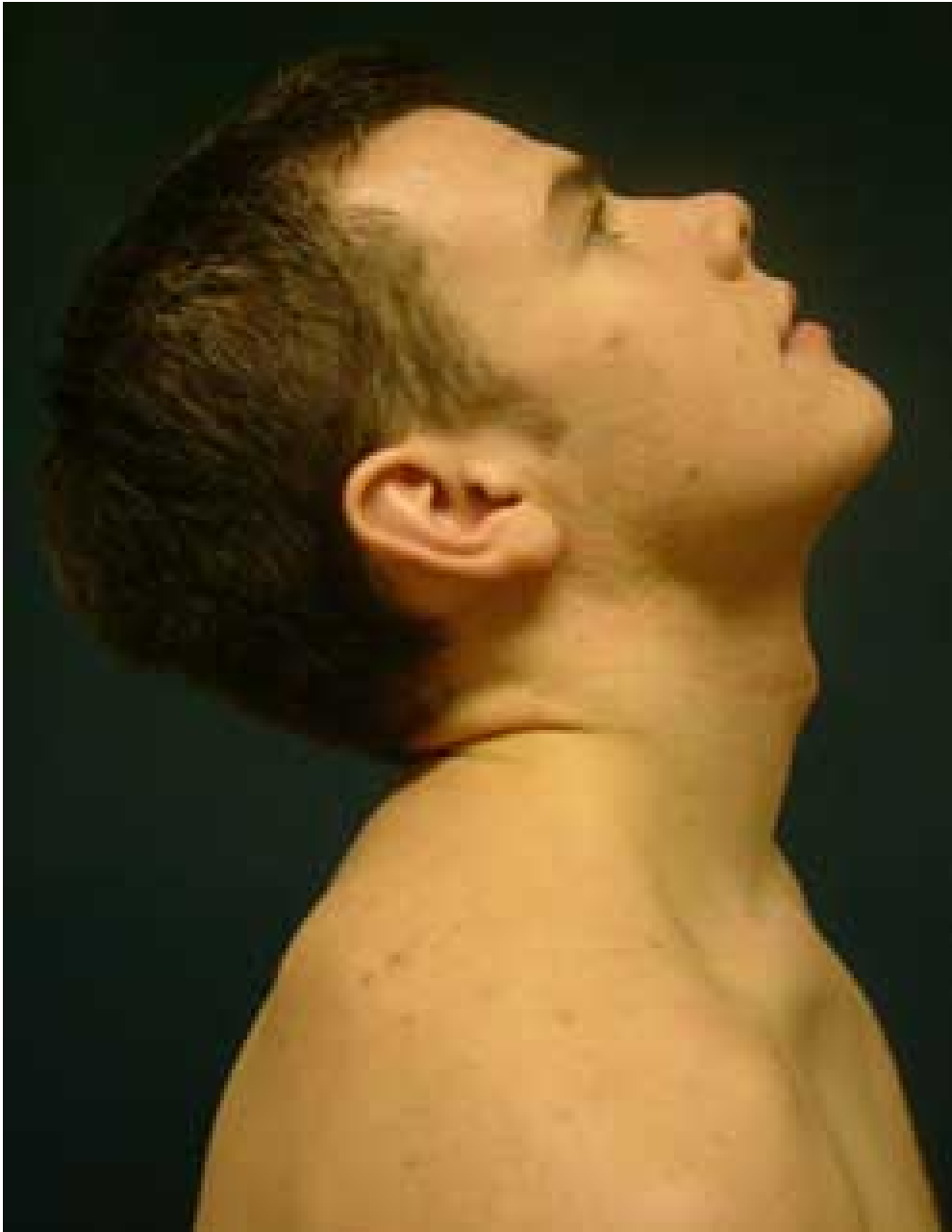

- Cervical spine flexion  
“Touch your chin on your chest”

# Measurement

- ask the patient to flex and extend head
- a spatula held in the mouth acts as a pointer to enable the range of movement to be measured by goniometer: normal range is 130 degrees.
- The occipito-atlantoid joint is primarily involved.



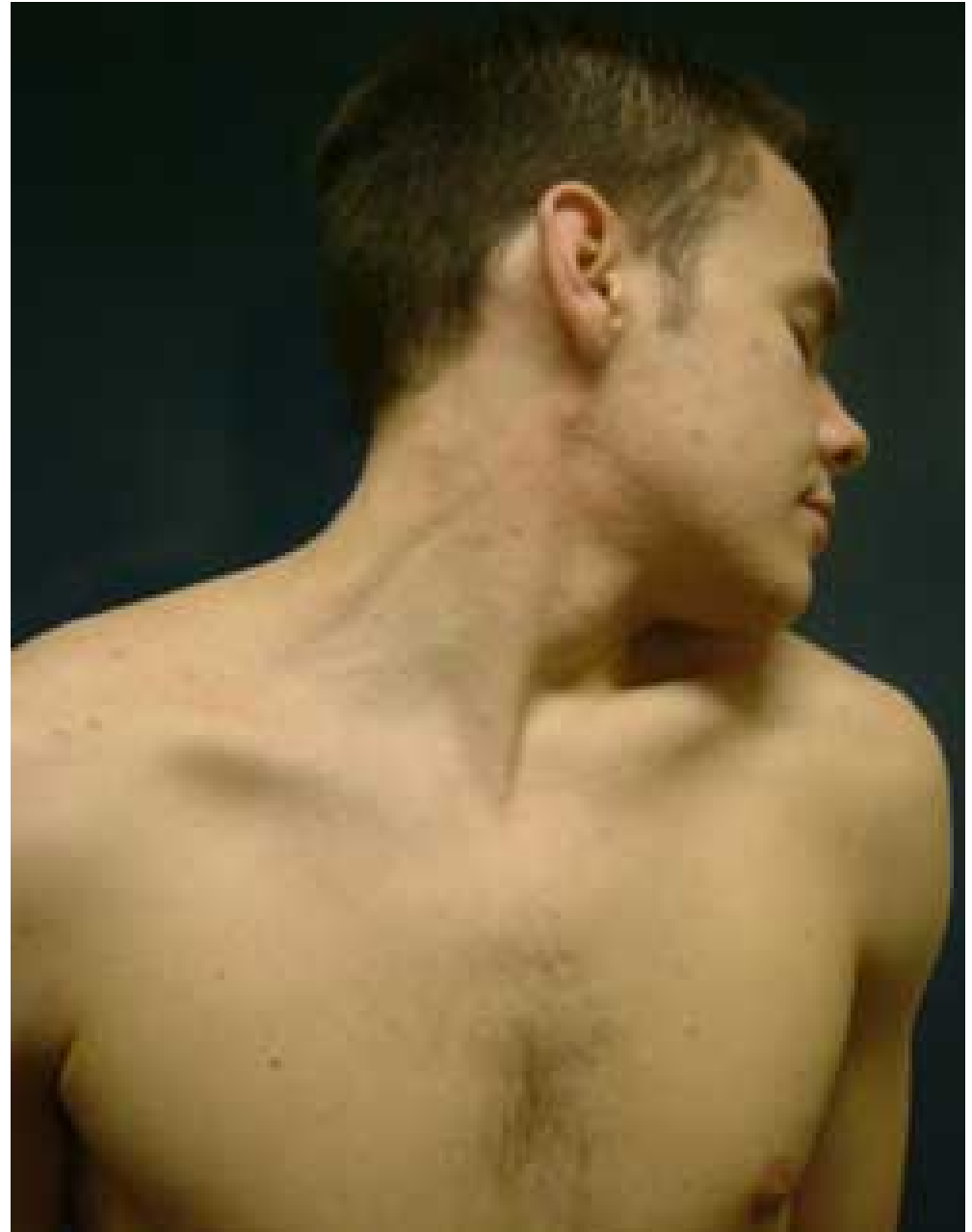

- Cervical spine extension  
“Look up and back”

- Lateral cervical spine flexion  
“Touch your shoulder with your ear”  
(Both sides)




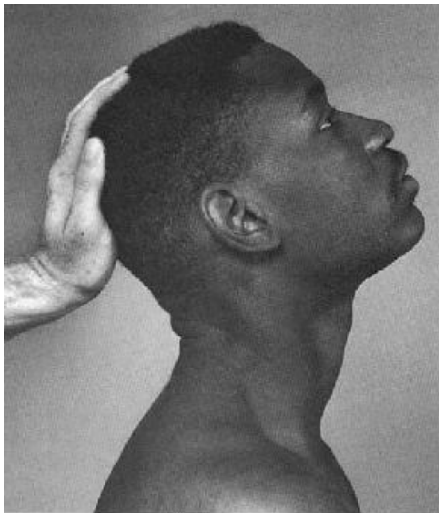

- Lateral cervical rotation (Both sides)  
“Touch your shoulder with your chin”



- lateral flexion: ask the patient to tilt his head laterally from a neutral position; normal range is 45 degrees.
- Whole of cervical spine involved.
- rotation: ask the patient to look over his shoulder
- normal range is 80 degrees to either side.
- Rotation is a function of the atlanto-axial joint.

# Muscle testing

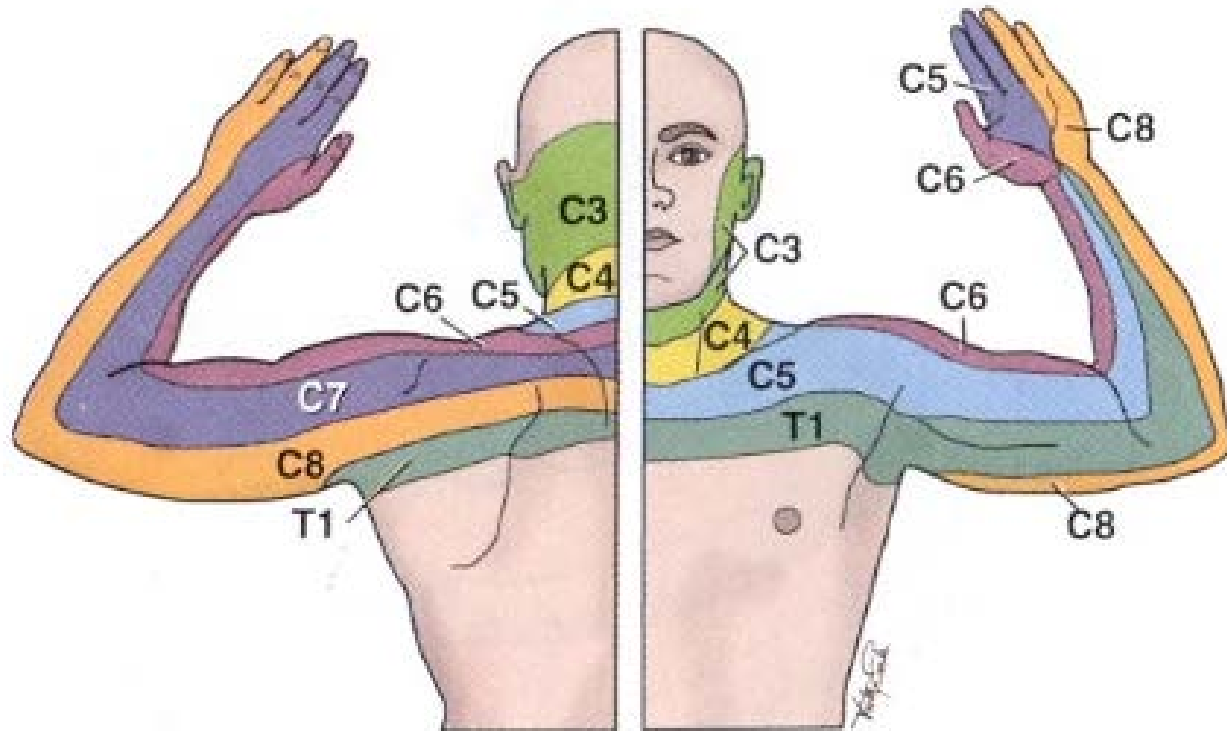
- All strength tests should be done gently , providing firm , control resistance.
- Lateral rotators: the sternocleidomastoid muscles function as both rotator and flexor, innervated by spinal accessory nerve ,isolated contraction rotates cervical spine , fired together principal flexor of neck.
- Extensors: posterior intrinsic muscles and upper portion of trapezius
- Lateral benders: powered by scalene



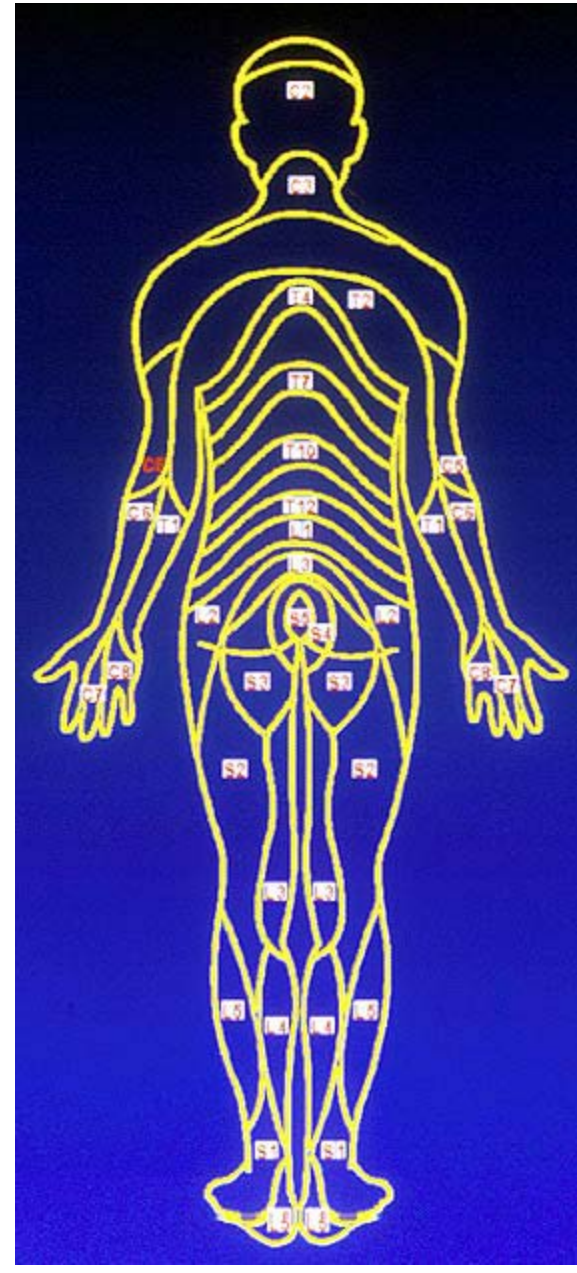
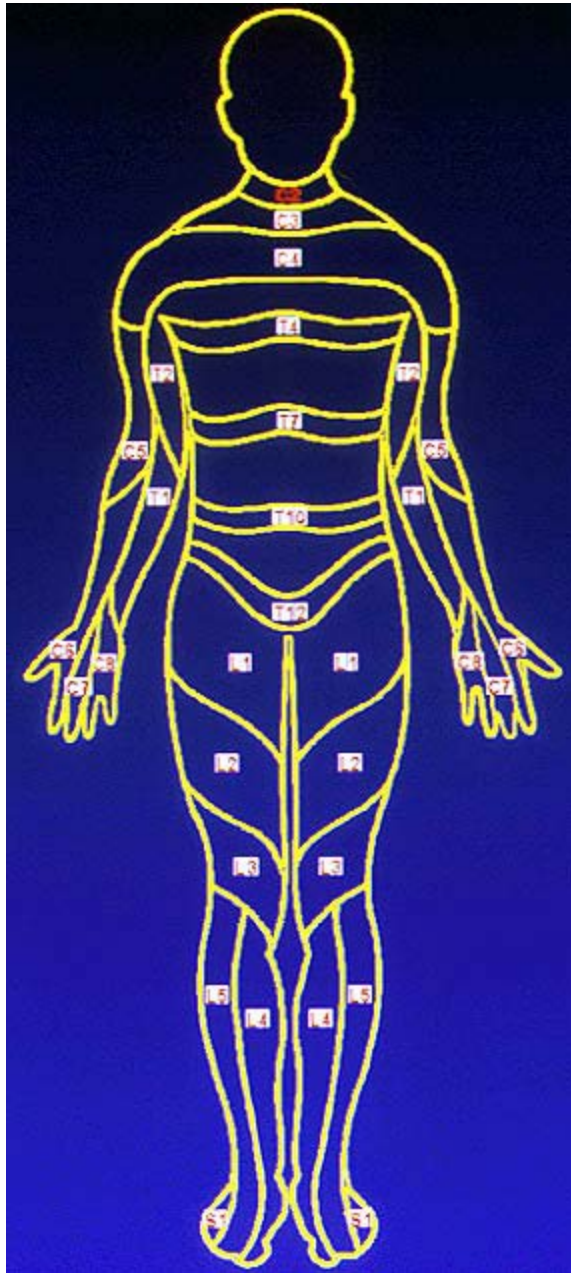
# Neurologic Examination

DERMATOME	SENSORY TESTING	MOTOR TESTING	REFLEX TESTING
C4	Lateral neck		
C5	Area over the middle deltoid	Deltoid Biceps brachii (secondary)	Biceps reflex
C6	Dorsum of the first web space and thumb	Biceps Brachii Wrist extensors	Brachioradialis reflex Biceps reflex (secondary)
C7	Long finger	Wrist flexors Long finger extensors Triceps brachii	Triceps reflex
C8	Little finger and ulnar side of hand	Long digital flexors (grip)	
T1	Medial arm at the elbow	Finger abduction and adduction (interossei)	
T2	Medial upper arm and adjacent chest		
T4	Nipple line		
T10	Umbilicus	Trunk flexion (Bevor's sign)	Abdominal muscle reflex

# Dermatomal distribution of the neck

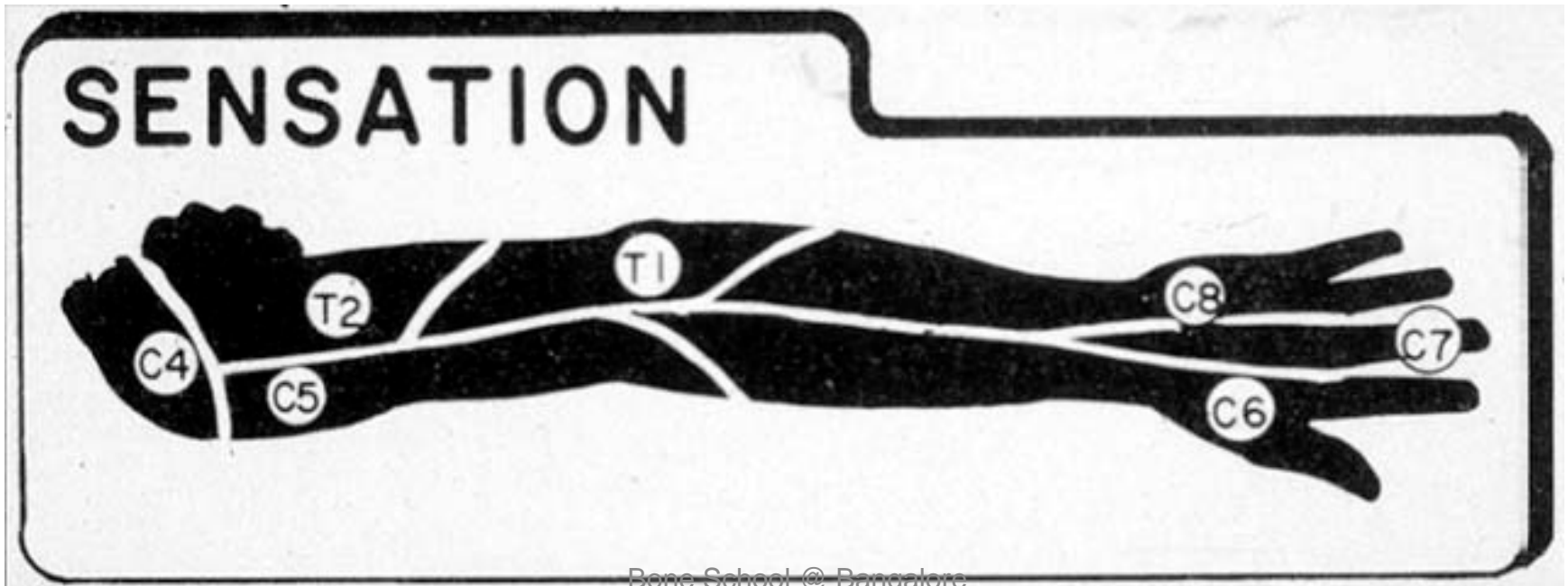




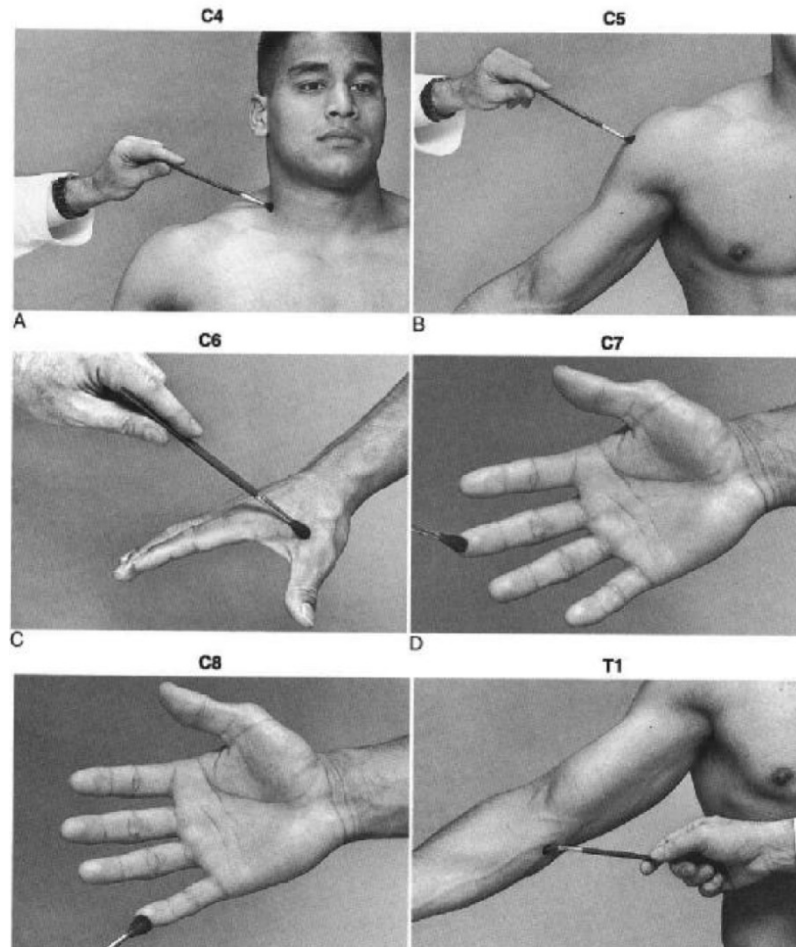


# *Sensation.*

- Know your C5 to T1 dermatomes.
- Test light touch and sharp/dull sensation.



# Sensory Evaluation by cervical dermatoms



# NEUROLOGICAL EVALUATION

## Motor Assessment (Cervical)

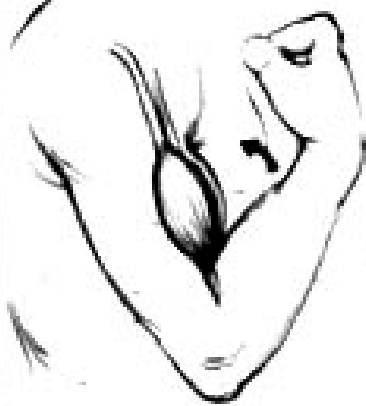C1/C2	suboccipital triangular muscle
C3/C4	diaphragm
C5	deltoid/shoulder int/ext rotators
C6	brachioradialis/wrist extensors ECRL/ECRB
C7	triceps, finger extensors (EDC)
C8	finger flexors (FDS/FDP)
T1	interossei

# MOTOR

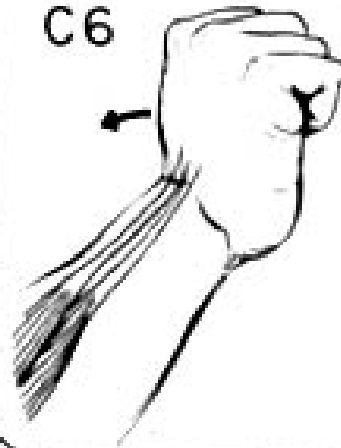
DELTOID  
C5



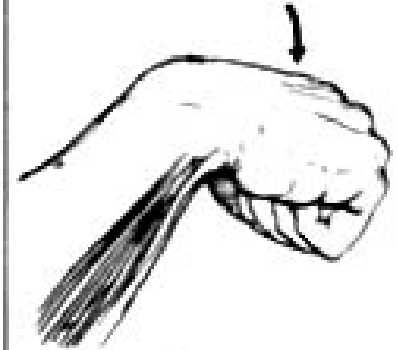
BICEPS  
C5,6



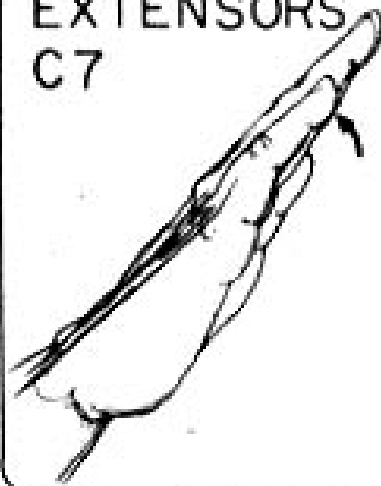
WRIST  
EXTENSORS  
C6



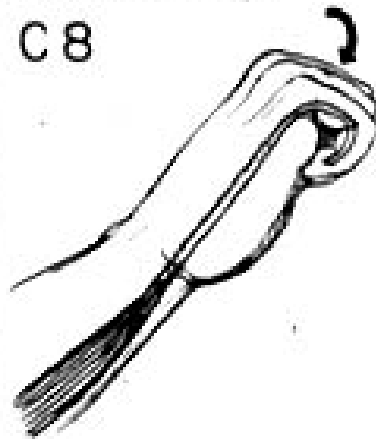
WRIST  
FLEXORS  
C7



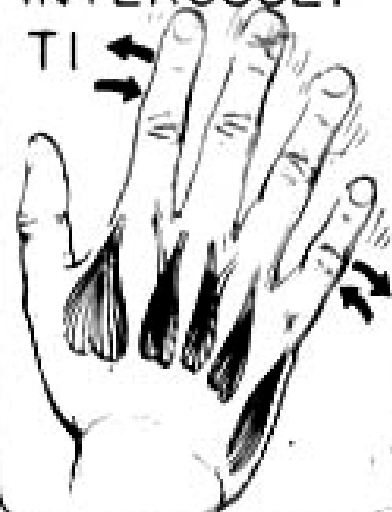
FINGER  
EXTENSORS  
C7



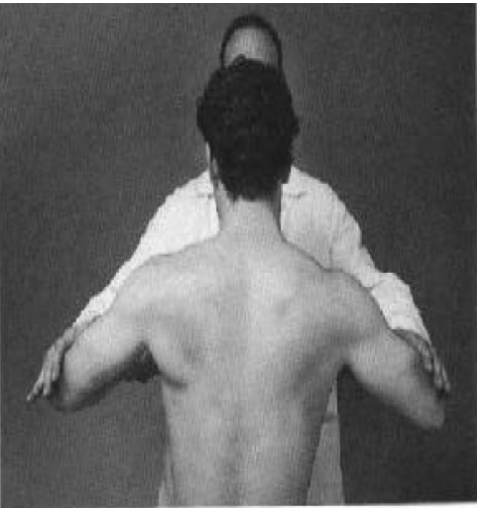FINGER  
FLEXORS  
C8



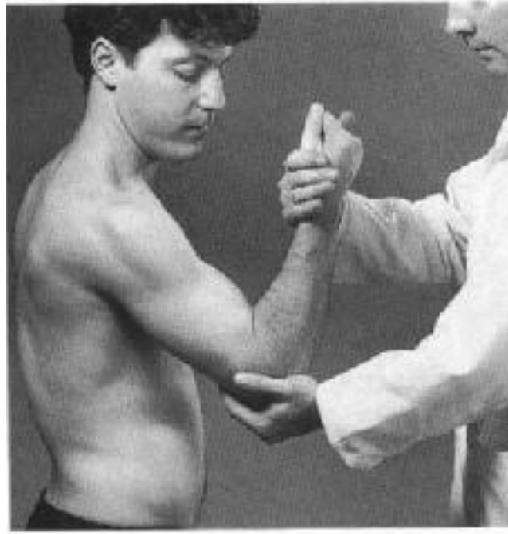
INTEROSSEI  
TI



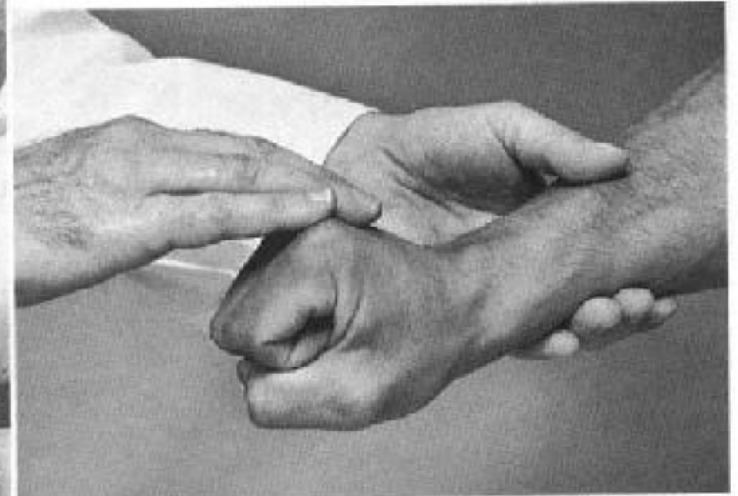
# Motor dermatomes Examination



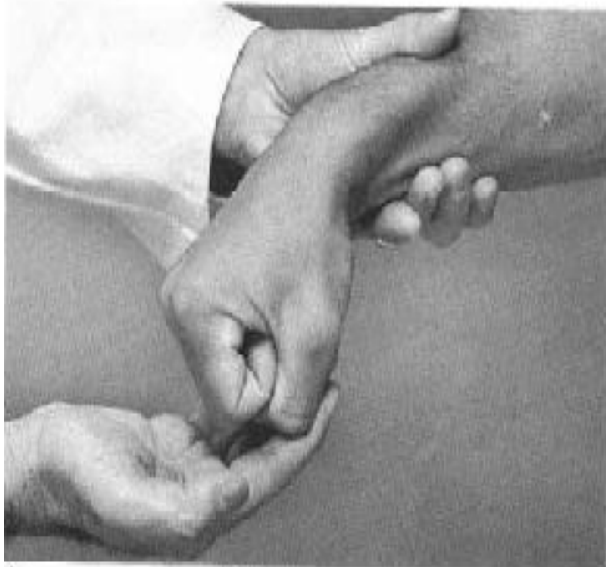C5



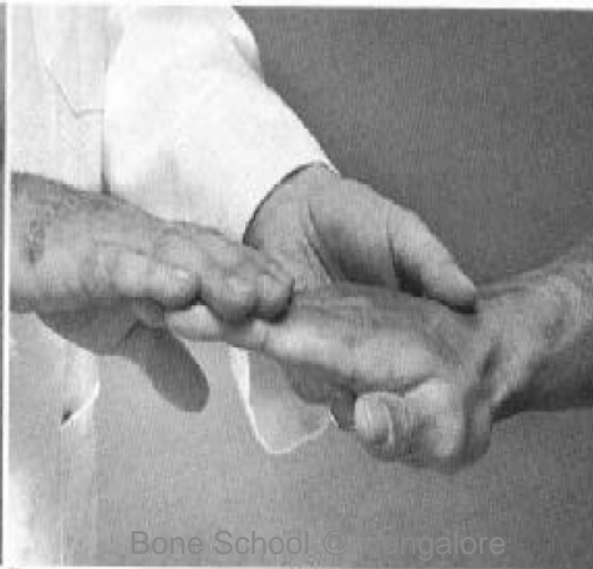C6



C6

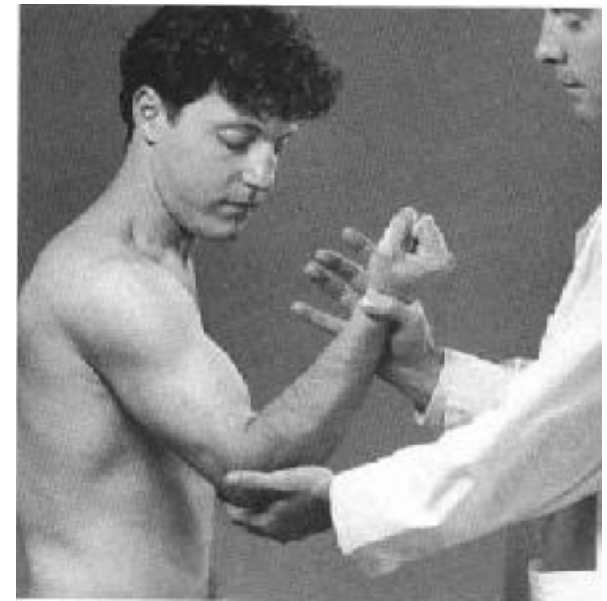


C7



Bone School © Bangalore

C7

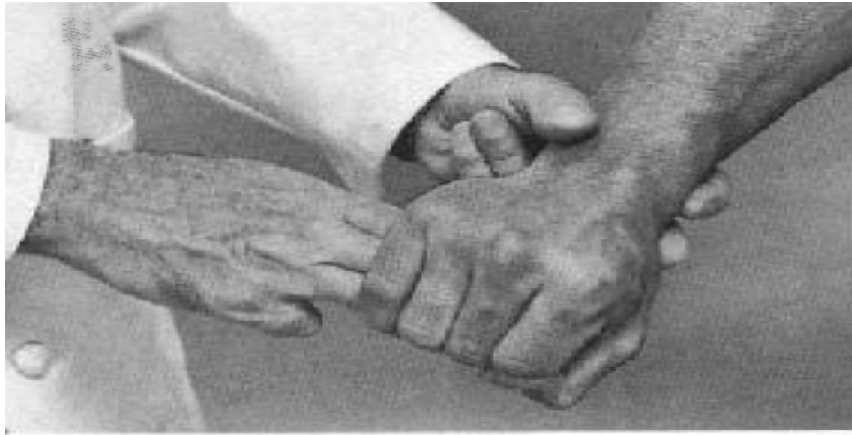

C7

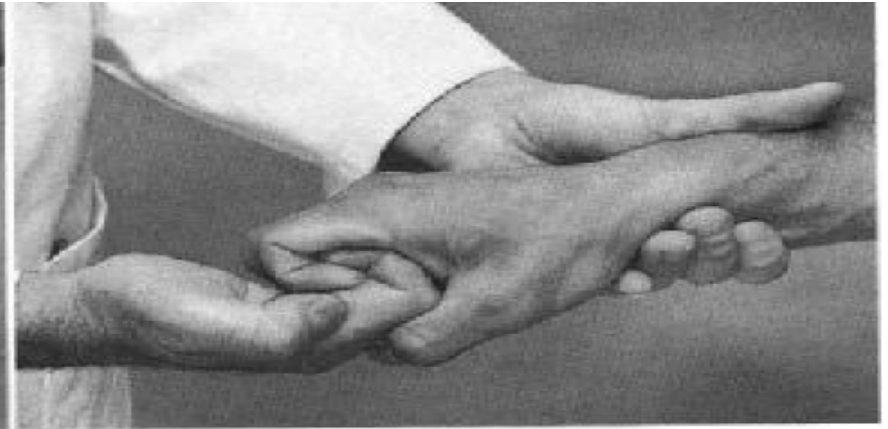
A

B

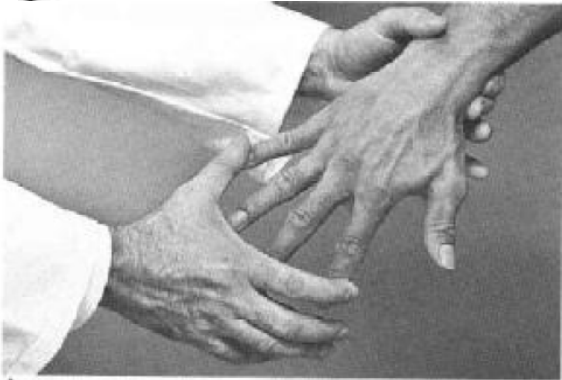C



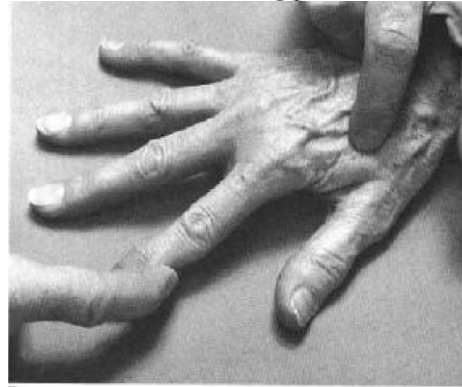**CB**



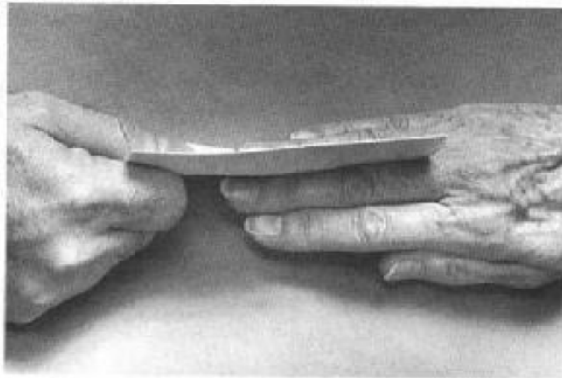
**CB**



**A**



**B**



**C**

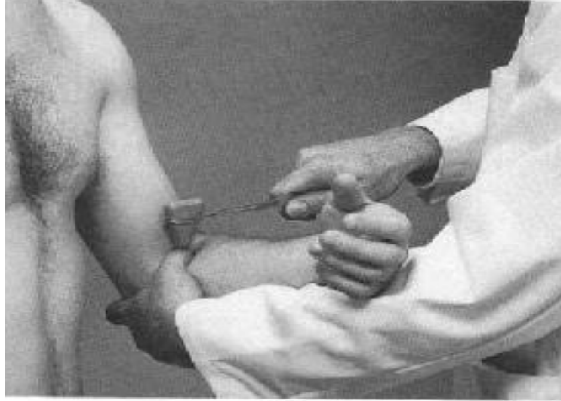
**T1**

# SEGMENTAL NEUROLOGY

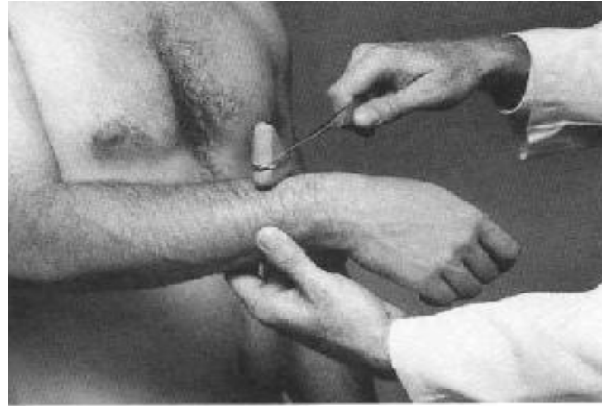- When examining the cervical spine it is essential to examine the segmental neurology.
- Root lesions may be indicated by weakness in the upper limbs in a segmental distribution, with loss of dermatomal sensation and altered reflexes.
- If cervical cord compression is suspected the lower limbs should also be examined specifically looking for upgoing planters and hyperreflexia.



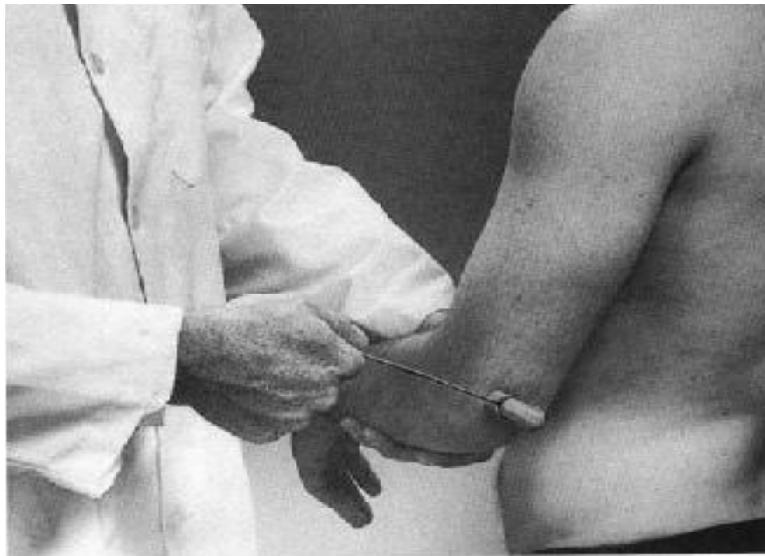# Reflexes



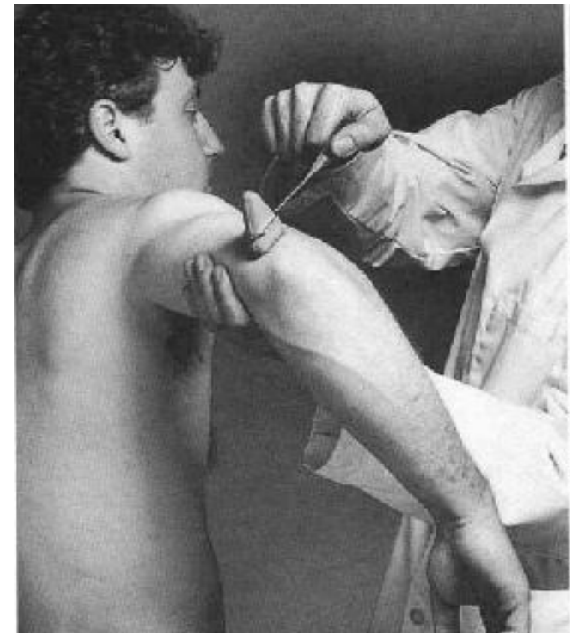C5



C6



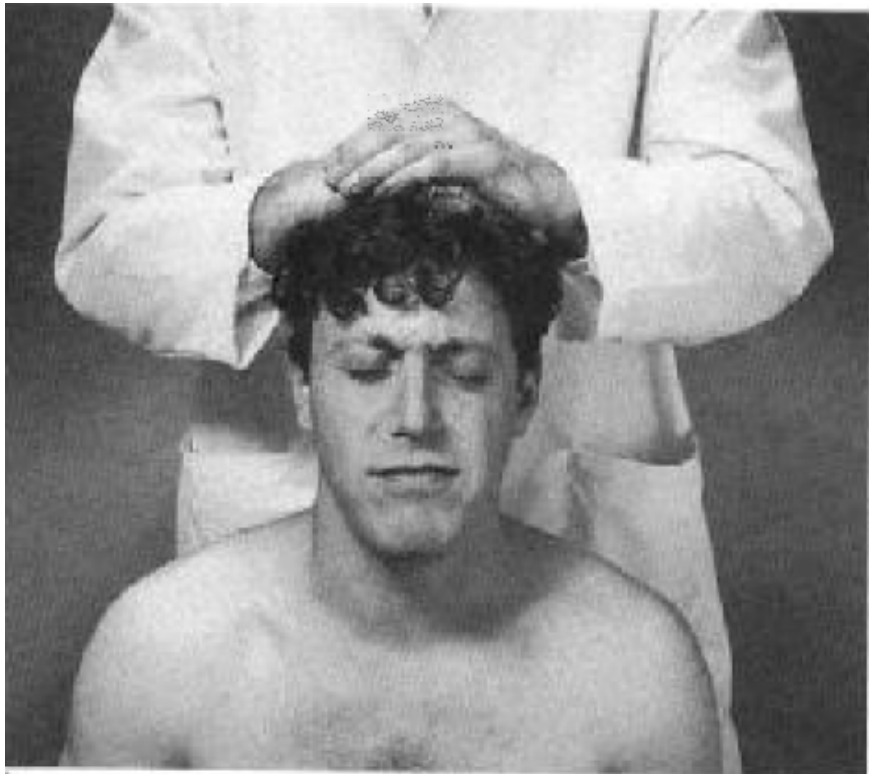C7



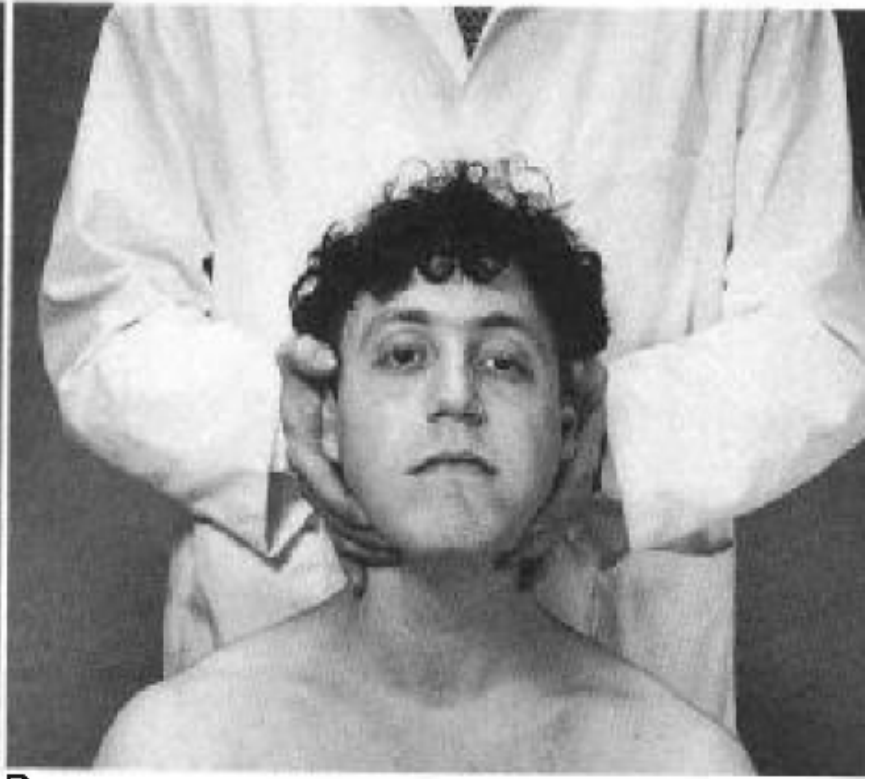
# REFLEXES

- *Muscle stretch reflexes.* Test the following reflexes:
- Biceps - C5/6
- Brachioradialis - C5/6
- Pronator - C 6/7
- Triceps - C7/8

- Axial compression test :Determine if axial compression test elicit patient's symptoms.
- It should not be performed when a nerve root compression with a motor neuron deficit is suspected.
- Distraction test : may relieve symptoms.



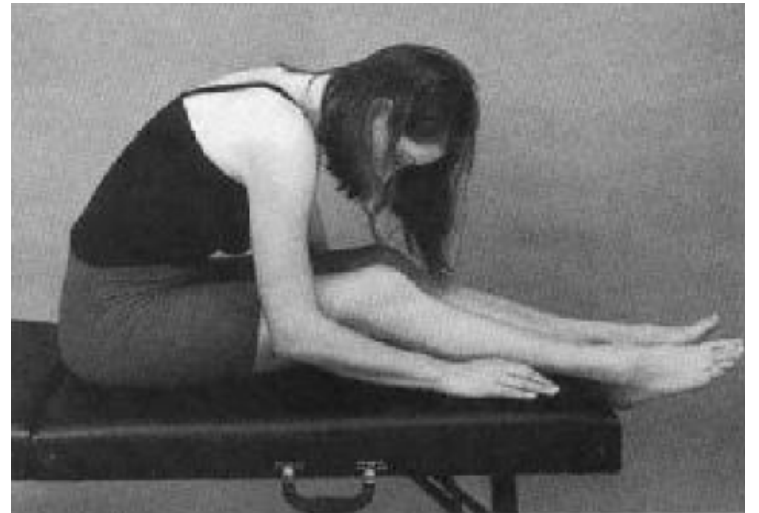
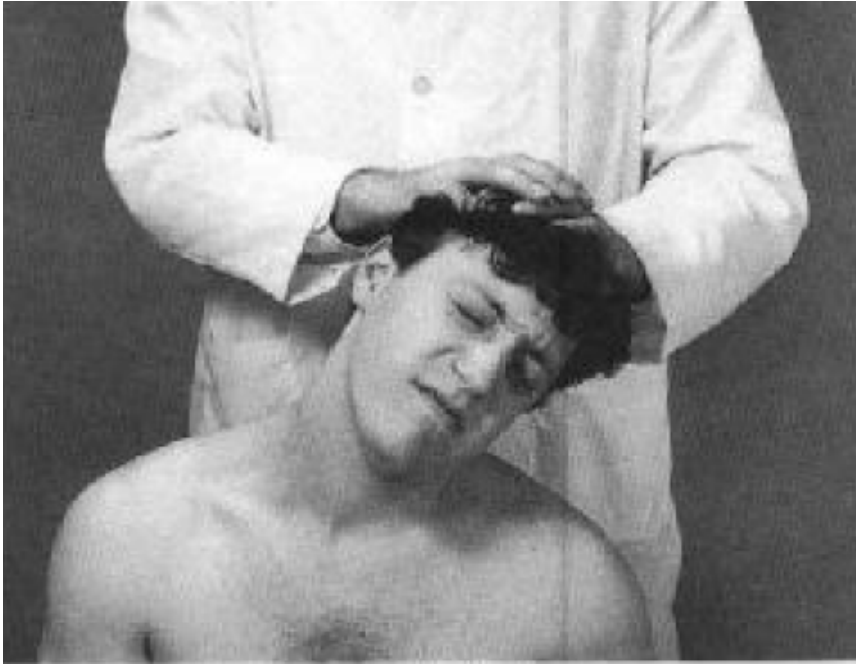
A



D

- ▶ Spurling 's test: in suspicious to lateralizing pathology such as a disk prolapsed , the neck is extended and rotated toward the involved side before the axial compression applied.
- ▶ It exacerbates encroachment on the nerve root by decreasing the dimensions of foramen.
- ▶ A patient may feel no discomfort , a sense of heaviness, nonradicular or pseudoradicular pain or radicular pain.
- ▶ Muscle strains or mild ligamenous sprains are not aggravated by test.
- ▶ Nonradicular or pseudoradicular pain radiates occiput, shoulder, scapula and arm , but not below the elbow. In spondylolisthesis and degenerative disk disease without root compression.

- Radicular pain radiates along the distribution of specific dermatoma. In young individuals is the result of nerve root compression due to intervertebral disk prolapsed , in older due to foramen stenosis .
- Lhermitt's maneuver: asking the seated patient maximally flex the cervical and thoracic spine
- Lhermitt's sign; the maneuver produces paresthesia in extremity or trunk, indicative spinal stenosis and resulting spinal cord compression.



# Thoracic & Lumbar Spine Physical Examination



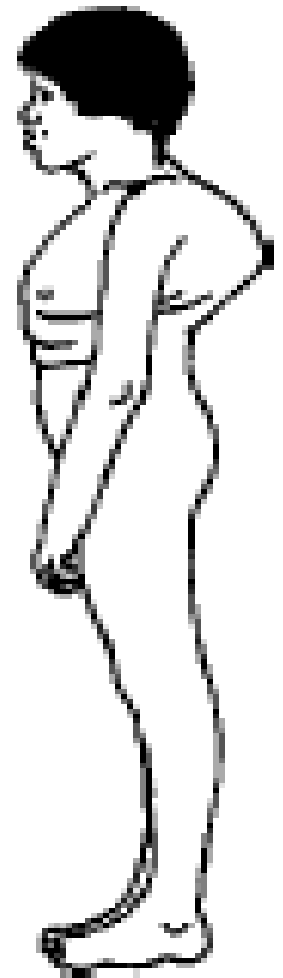1. Inspection
2. Gait
3. Movements
4. Sitting examination
5. Supine examination
6. Prone examination

# Inspection of thoracic spine

- General observation of the standing patient.
- Look for posture, symmetry, leg length discrepancy, skin (colour, scars, lesions, creases), muscle wasting, joint swelling.
- *Gait.*
- Have the patient walk normally then on their toes (tests S1) then on their heels (tests L4/5).
- Observe for abnormal gait patterns including
- Antalgic, Trendelenburg, Short leg, Foot drop

# Deformities

- Deformities of the thoracic spine are both common and important.
- Scoliosis:
- Kyphosis:
- Lordosis:
- this may be seen but is rarely a serious problem



# Inspection of lumbar spine

- scoliosis is best seen with the patient leaning forward.
- The normal lordosis of the lumbar spine may be flattened by muscle spasm.
- Accentuation of the lordosis is rarely serious.

# Thoracic spine

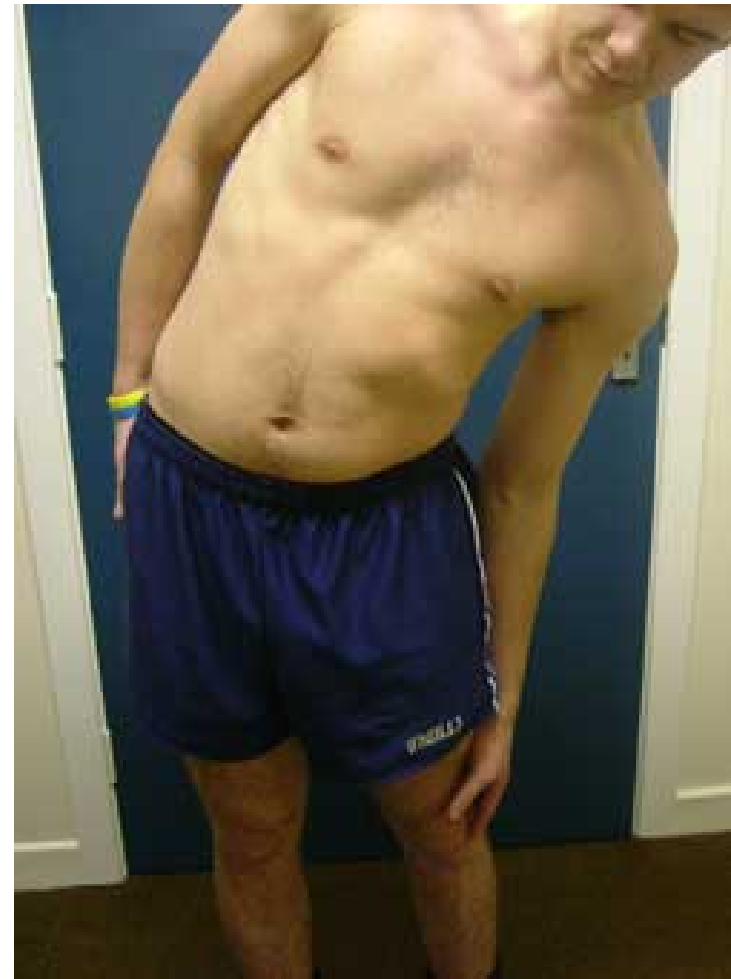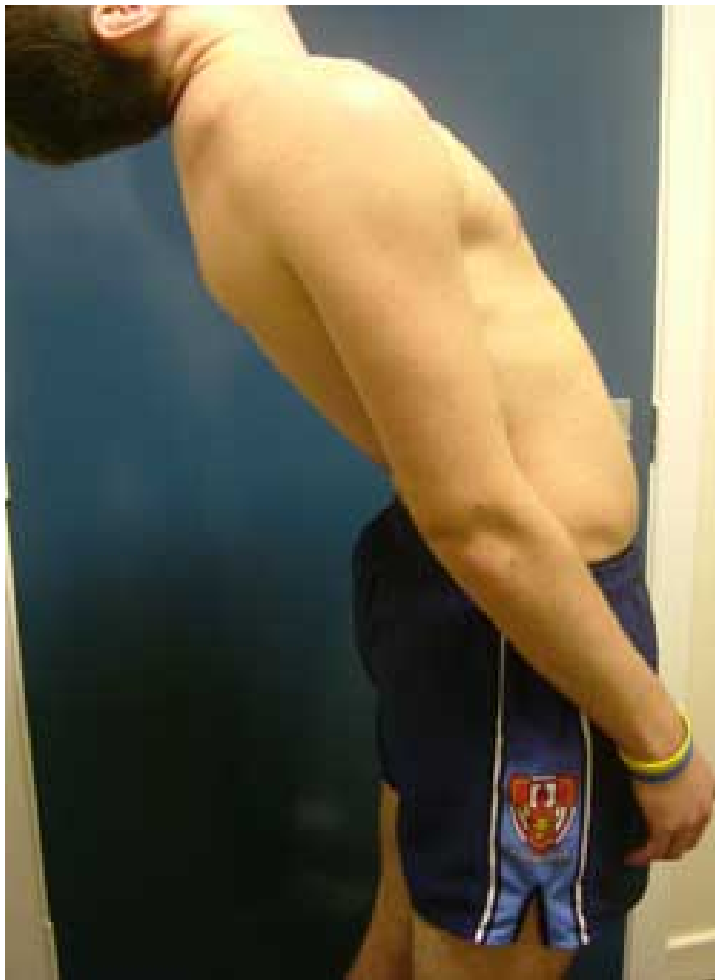- Tenderness is elicited by light percussion of the spinous processes of the thoracic spine, with the patient leaning forward.
- Rotational stress from the side.
- in cases of lumbosacral junctional spondylolisthesis tenderness may be accompanied by a palpable step.

# Active range of motion.

- Ask the patient to perform the following manoeuvres:
- Forward flexion - note the finger tip to floor distance
- Extension - record as a % of normal



Lumbar flexion  
“Try to touch your toes  
without bending  
knees”



**Lumbar extension**  
**Lean back”**

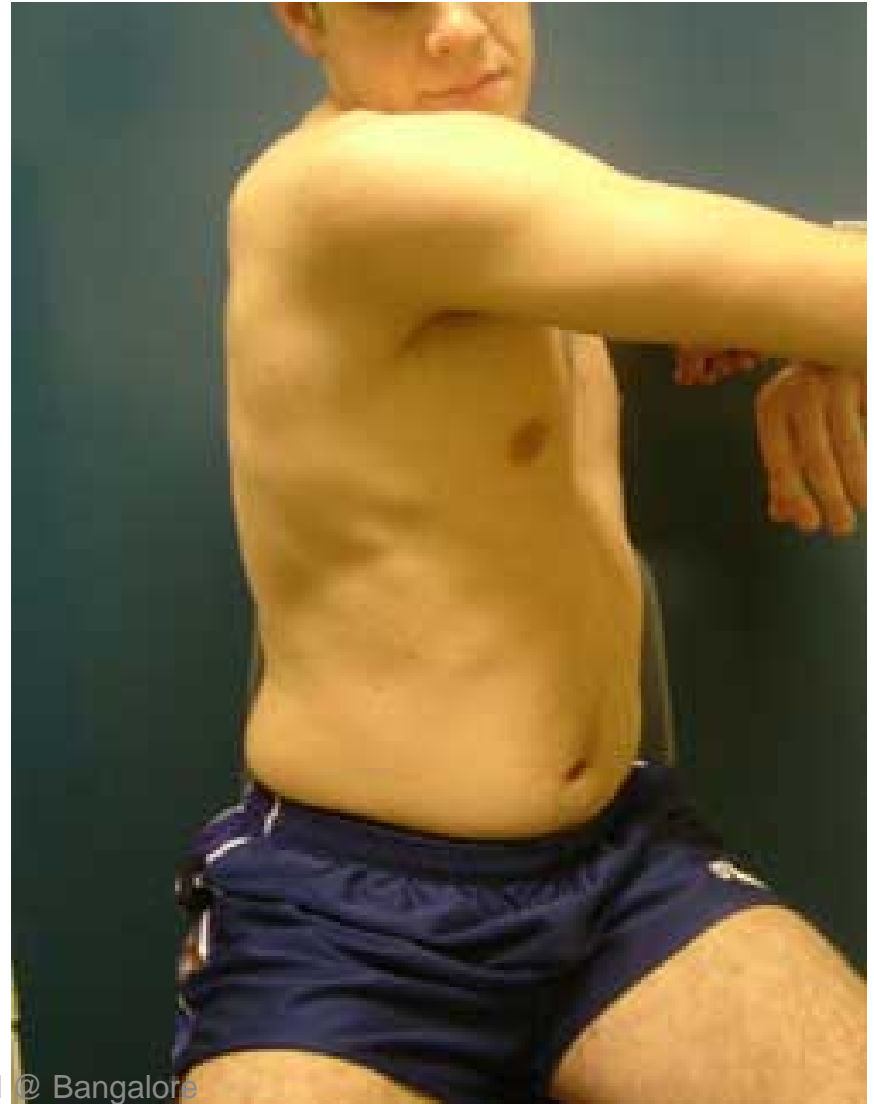**Lateral lumbar flexion (Both sides) “Slide your hand down your leg”**

**•Lateral flexion - note the finger tip to floor distance**



# Thoracolumbar rotation

- Rotation - record using degrees
- “Sit down and turn round, looking over your shoulder”  
(Sitting down helps fix the patients pelvis)

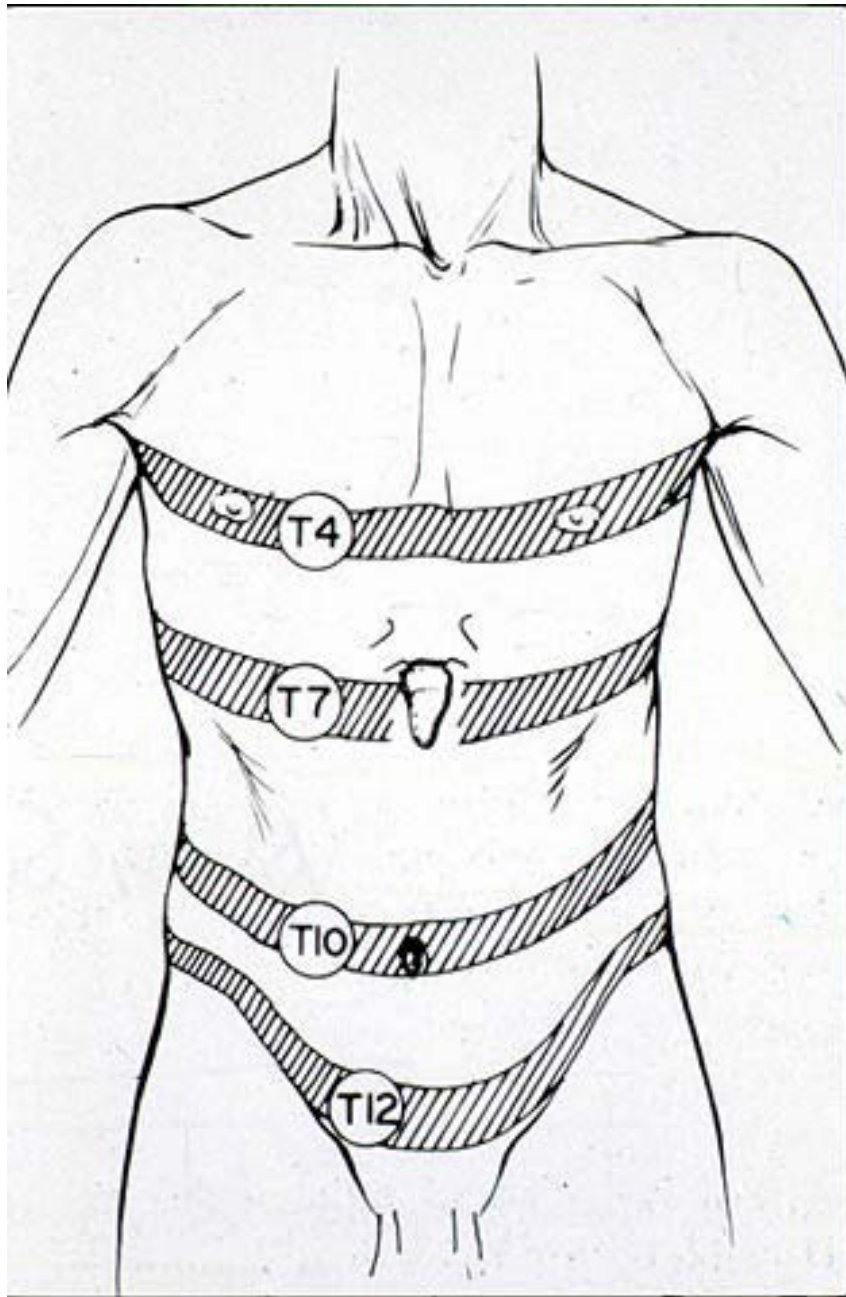


# Sitting examination.

- Perform the following examinations:
- Straight leg raising
- Muscle stretch reflexes
  - Quadriceps - L4
  - Gastroc/soleus - S1
- Muscle power
  - Knee extension - L3/4
  - Knee flexion - L4/5

# Supine examination.

- Perform the following examinations:
- Straight leg raising
- reflexes
- Muscle power
- Examine hip joints
- Examine sacro-iliac joints



## Sensory Assessment (Thoracic)

- T4 - Nipple line
- T7 - Xyphoid Process
- T10 - Umbilicus
- T12 - Groin

# Clinical Evaluation

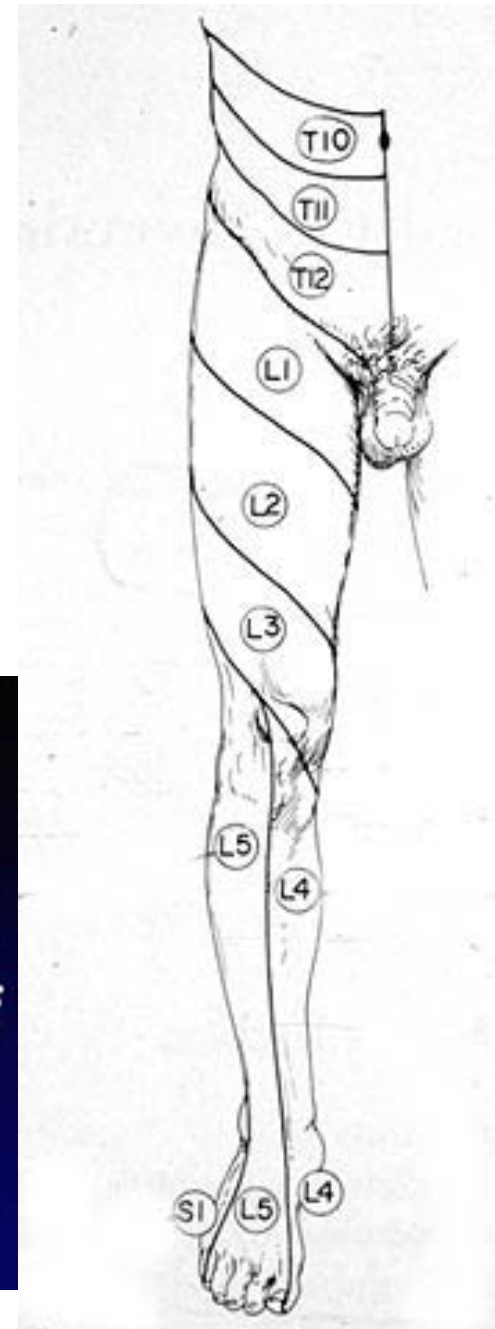
## *Lower Quarter Neurological Screen*

<b>Nerve Root Level</b>	<b>Sensory Testing</b>
<b>L1</b>	<b>Inguinal area (just below inguinal ligament)</b>
<b>L2</b>	<b>Mid-thigh (medial)</b>
<b>L3</b>	<b>Medial knee (just above superior pole of patella)</b>
<b>L4</b>	<b>Medial aspect of lower leg, medial ankle, big toe</b>
<b>L5</b>	<b>Top of foot (an/or blow head of fibula)</b>
<b>S1</b>	<b>Lateral foot</b>
<b>S2</b>	<b>Posterior thigh, popliteal fossa</b>

- Sensation
- Know your L4 to S1 dermatomes
- Light touch, sharp/dull sensation

## Sensory Assessment (Lumbosacral)

L1/L2 Inguinal region/inner thigh  
 L3/L4 Anterior/anterolateral knee/medial calf  
 L5 Lateral calf/Dorsal foot  
 S1 posterior calf/lateral and plantar foot  
 S2-S5 perineum



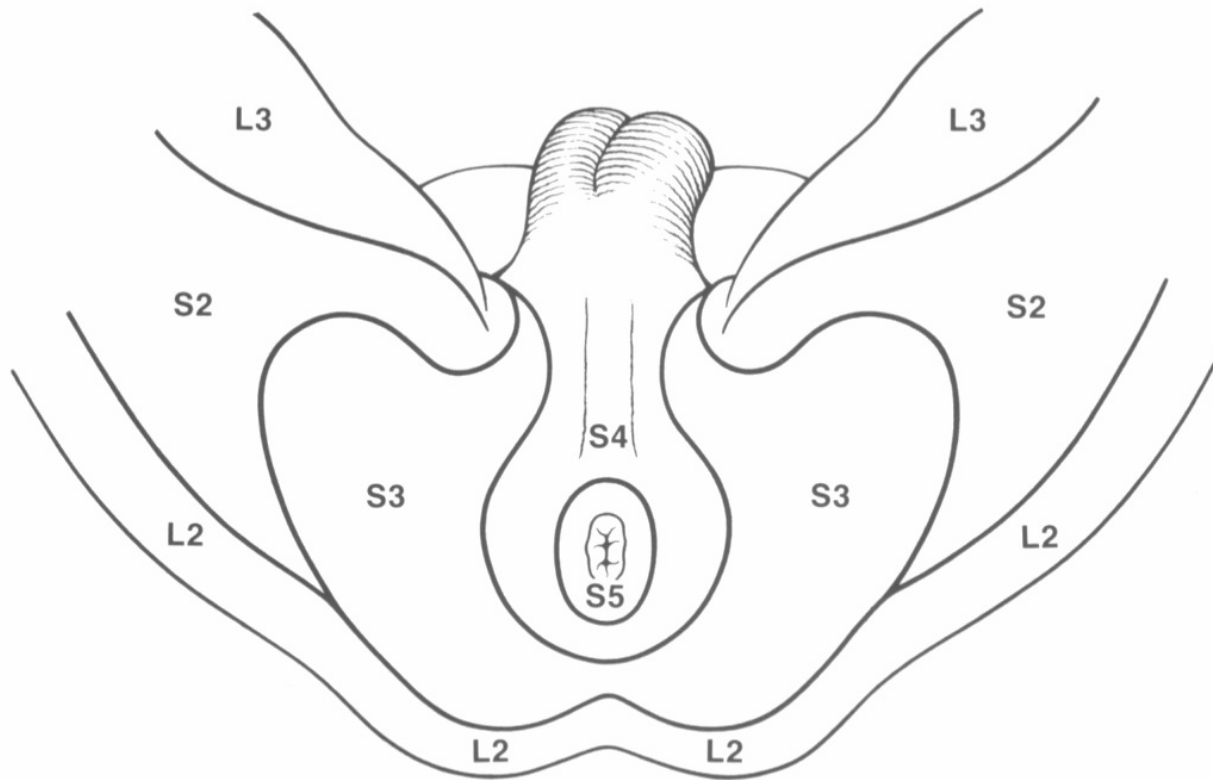


Fig. 90 Approximate distribution of dermatomes on the perineum.

# Prone examination

- Perform the following examinations:
- Muscle power
  - Hip extension with knee flexed - S1
- Prone extension test (femoral stretch test)
- Palpation



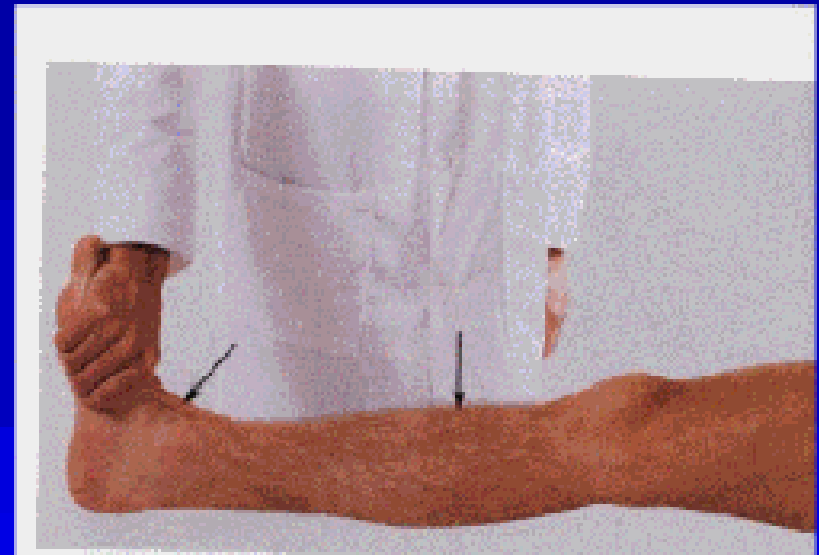
# Clinical Evaluation

## *Lower Quarter Neurological Screen*

<b>Nerve Root Level</b>	<b>Motor Testing</b>
<b>L1</b>	<b>Hip flexion</b>
<b>L2</b>	<b>Hip flexion</b>
<b>L3</b>	<b>Knee extension</b>
<b>L4</b>	<b>Dorsiflexion</b>
<b>L5</b>	<b>Great toe extension</b>
<b>S1</b>	<b>Plantarflexion</b>
<b>S2</b>	<b>NA</b>

# L4 Root Compression

- Decreased strength in ankle dorsiflexion (tibialis anterior) and also in leg extension (quadriceps)
- Decreased sensation along medial aspect of lower leg
- Decreased patellar reflex and problem with heel walking



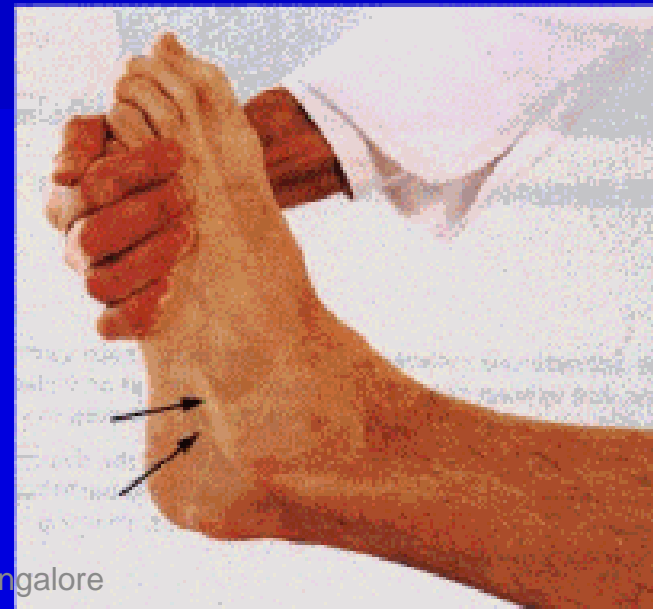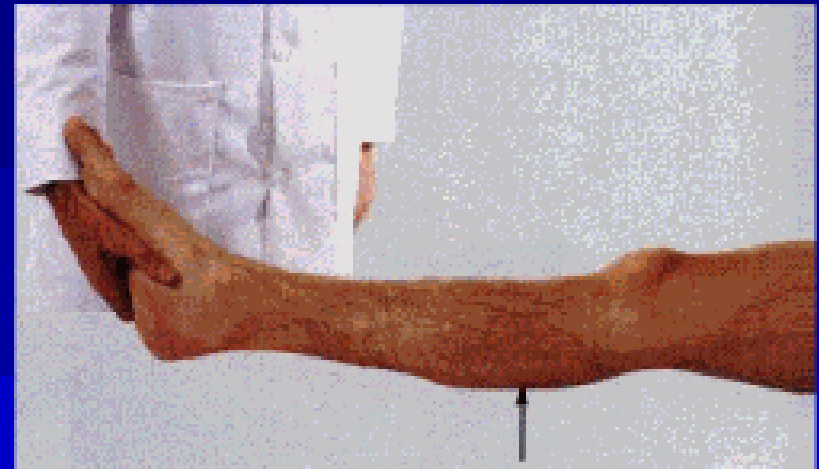# L5 Root Compression

- Weakness of extensor hallicus longus and extensor digitorum longus
- Decreased sensation along lateral leg and web of great toe



# S1 Root Compression

- Weakness in plantar flexion (gastrocnemius and soleus) and weakness with eversion of ankle
- Decreased sensation along lateral foot, plantar aspect of foot and heel
- Decreased ankle reflex



# Reflexes

Important in determining the nature (cord vs peripheral nerve) and the extent (partial vs complete) of neurologic injury

# Reflex Assessment (Thoracic)

T7-T10 - Upper Quadrant Abdominals

T10-L1 - Lower Quadrant Abdominals

# Reflexes (Lumbosacral)

L1 - Lower Abdominals; Cremasteric Reflex

L2/L3/L4 - Patellar Tendon (mostly L4)

L5 - None

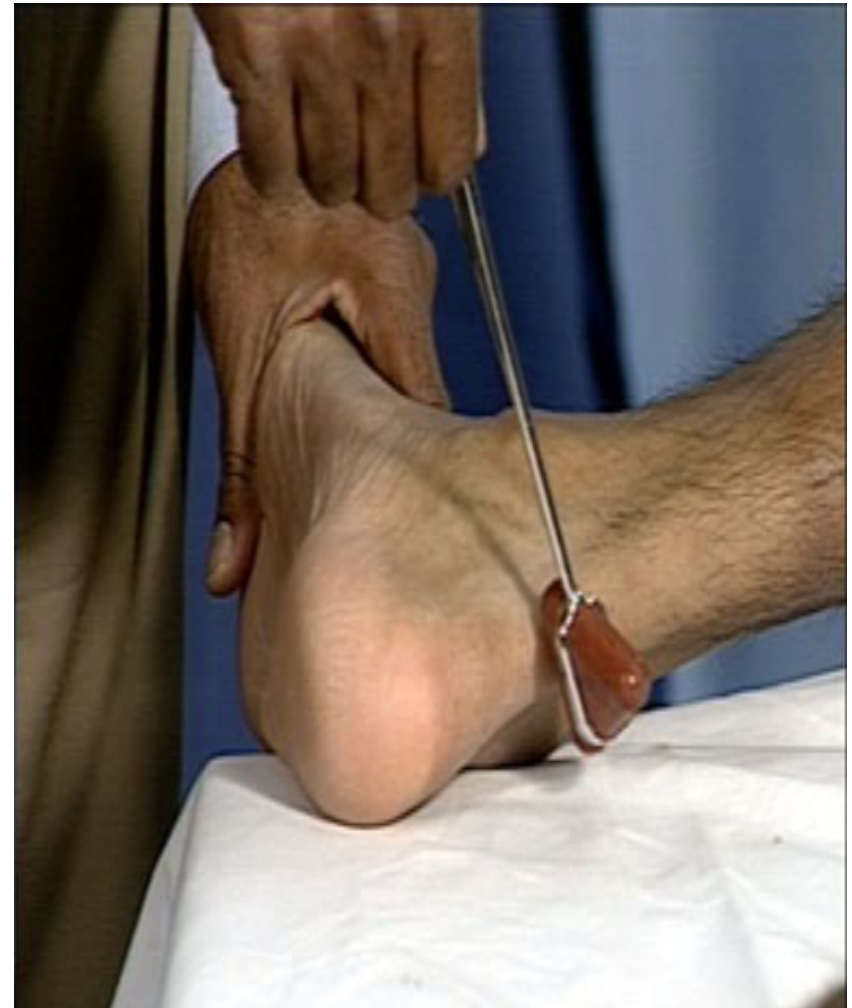S1 - Achilles Tendon

S2/S3/S4/S5 - Superficial Anal Reflex  
(Wink)

# Clinical Evaluation

## *Lower Quarter Neurological Screen*

<b>Nerve Root Level</b>	<b>Reflex Testing</b>
<b>L4</b>	<b>Patellar Tendon</b>
<b>L5</b>	<b>Patellar Tendon</b>
<b>S1</b>	<b>Achilles Tendon</b>
<b>S2</b>	<b>Achilles Tendon</b>





# Clinical Evaluation

- ***Sacroiliac Dysfunction:***

- **History:**

- **Onset:**

- Acute or insidious

- **Pain characteristics:**

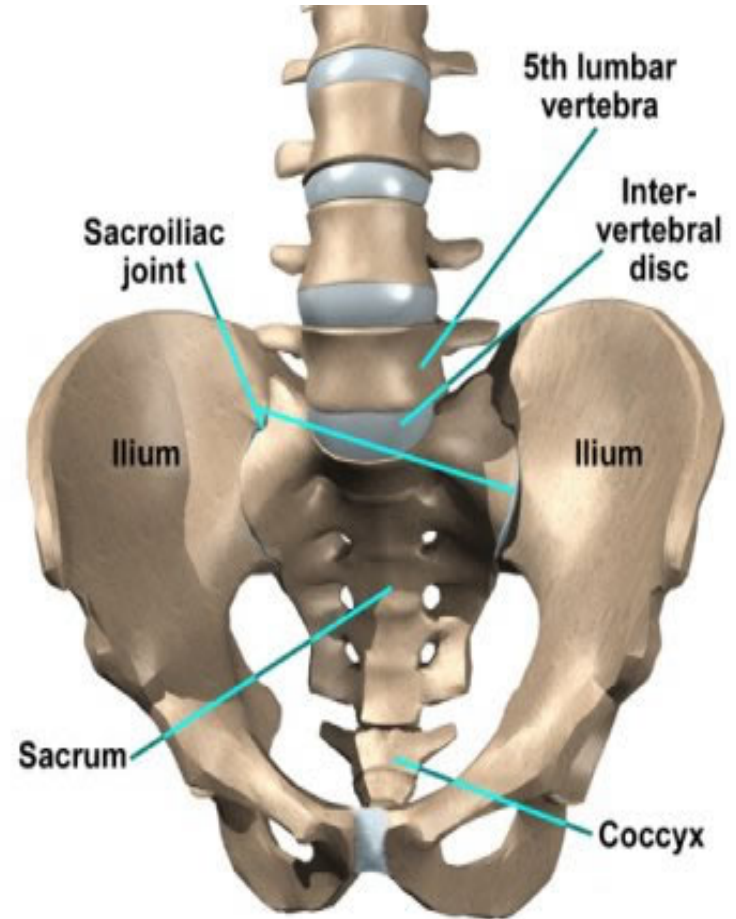
- One or both SI joints; possibly radiating pain in buttocks, groin, thigh

- **Mechanism:**

- Prolonged stress

- **Predisposing conditions:**

- Postpartum women (relaxin levels)
- Hormonal levels during menstruation



# Clinical Evaluation

- ***Sacroiliac Joint Dysfunction:***

- **Inspection:**

- Levels of iliac crests, ASIS, PSIS

- **Palpation:**

- Pain over SI joints and PSIS

- **Functional tests:**

- Trunk flexion (with knees extended) will cause movement of the sacrum on the ilia (pain)

- **Neurological testing:**

- Lower quarter screen

- **Special tests:**

- Long sit; SI compression and distraction; straight leg raising; fabre; gaenslen's; quadrant

# Clinical Evaluation

- ***Sacroiliac Joint Stress Test:***

- **Test position:**

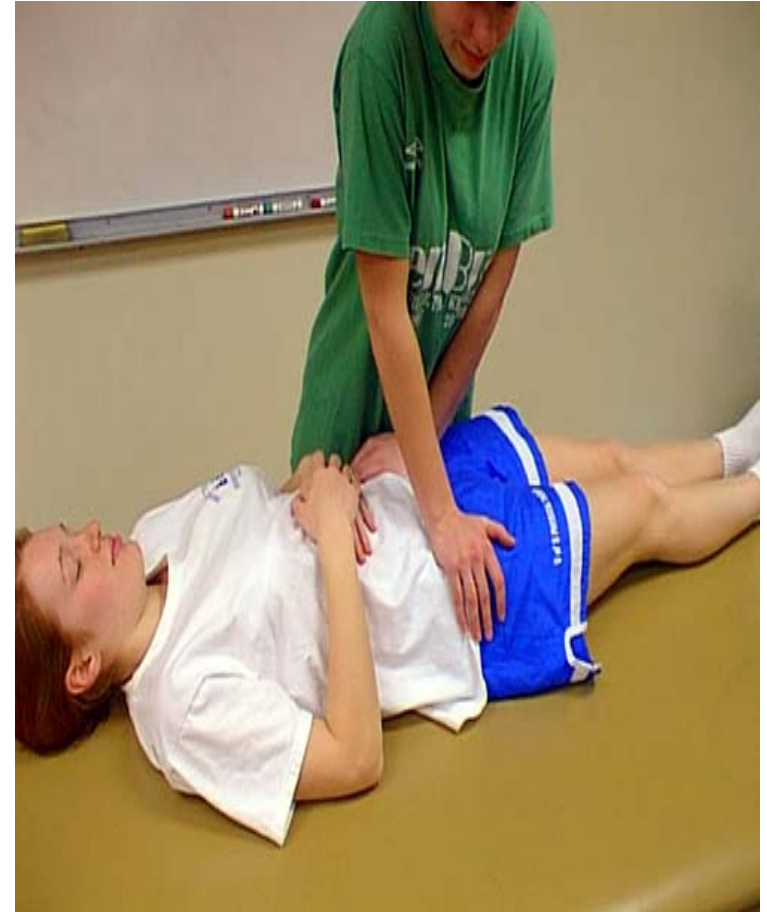- Subject supine; examiner stands next to subject and with arms crossed, places heel of both hands on the subject's ASISs

- **Action:**

- Examiner applies outward and downward pressure with the heels of both hands

- **Positive finding:**

- Unilateral pain at SI joint or in gluteal/leg region is indicative of anterior SI ligament sprain



# Clinical Evaluation

- ***Sacroiliac Joint Stress Test:***

- **Test position:**

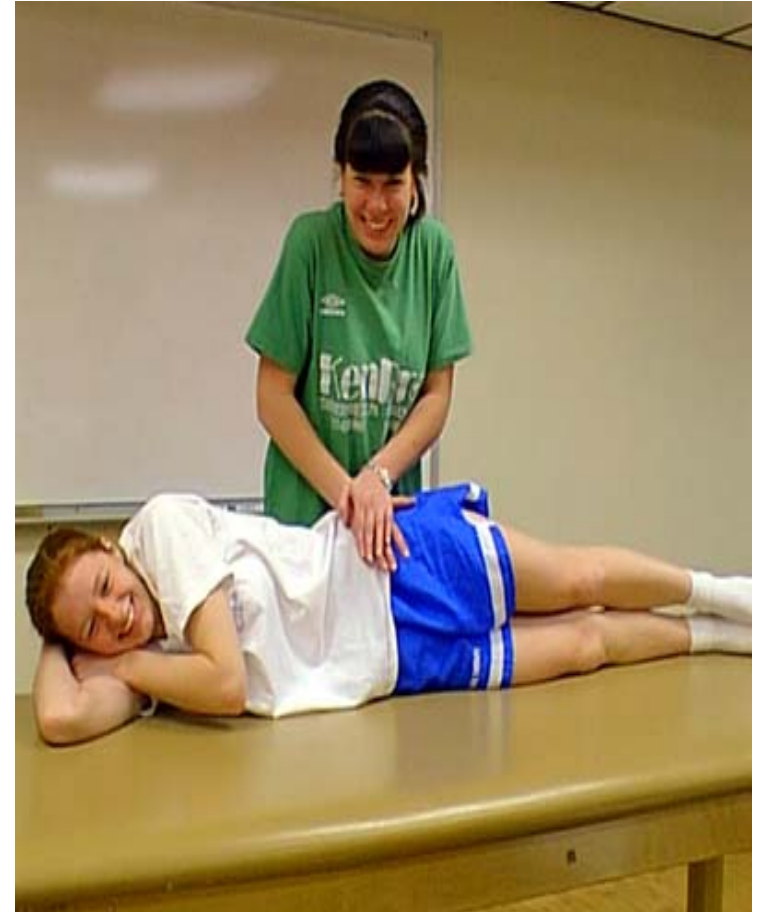- Subject side-lying; examiner stands next to patient and places both hands (one on top of the other) directly over the subject's iliac crest

- **Action:**

- Apply downward pressure

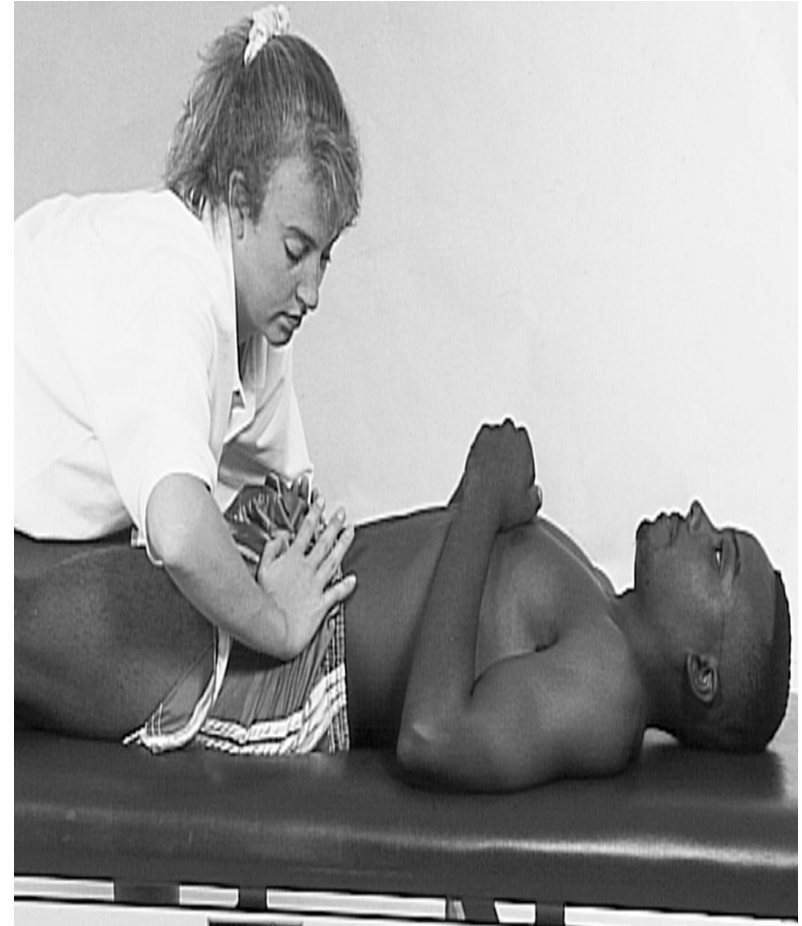
- **Positive finding:**

- Increased pain indicative of SI pathology (possible involvement of posterior SI ligament)



# Clinical Evaluation

- ***Sacroiliac Joint Stress Test:***
  - **Test position:**
    - Subject lying supine; examiner places both hands on lateral aspect of subject's iliac crests
  - **Action:**
    - Apply inward and downward pressure
  - **Positive finding:**
    - Increased pain indicative of SI pathology (possibly involving posterior SI ligaments)



# Clinical Evaluation

- ***Sacroiliac Joint Stress Test:***

- **Test position:**

- Subject lying prone; examiner places both hands (one on top of the other) over subject's sacrum

- **Action:**

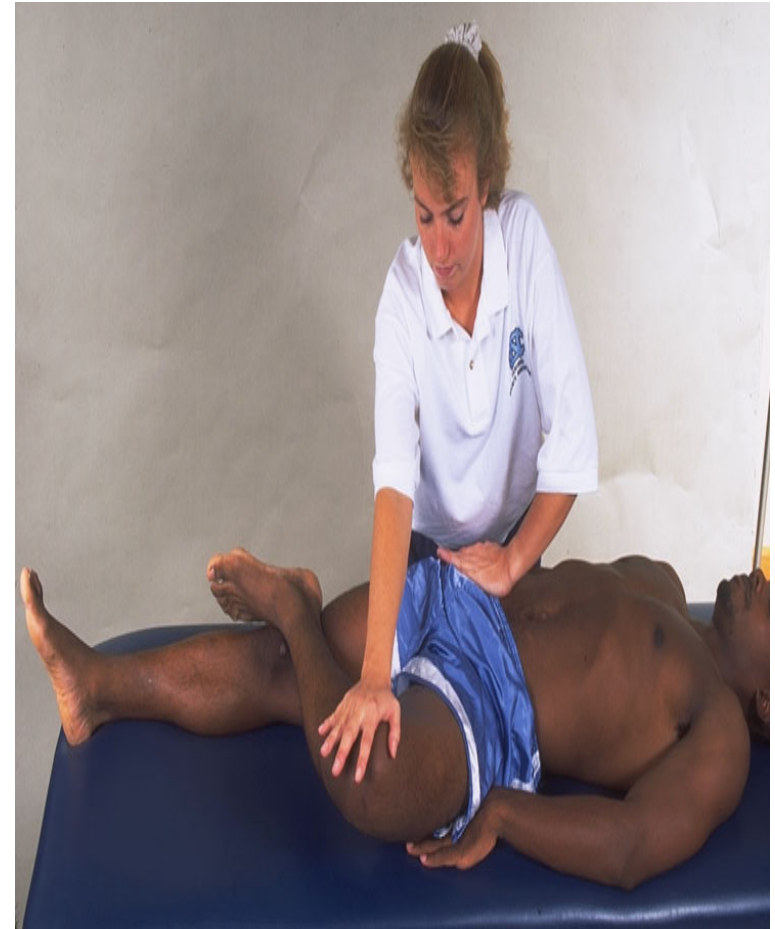- Apply downward pressure on sacrum

- **Positive finding:**

- Increased pain indicative of SI pathology

# Clinical Evaluation

- **Patrick or FABER Test:**
  - **Test position:**
    - Subject supine
  - **Action:**
    - Examiner passively flexes, abducts, and externally rotates the involved leg until the foot rests on the top of the knee of uninvolved lower extremity; examiner slowly abducts the involved lower extremity towards the table
  - **Positive test:**
    - Involved lower extremity does not abduct below level of uninvolved side
      - SI pathology, iliopsoas tightness



# Clinical Evaluation

- ***Gaenslen's Test:***

- **Test position:**

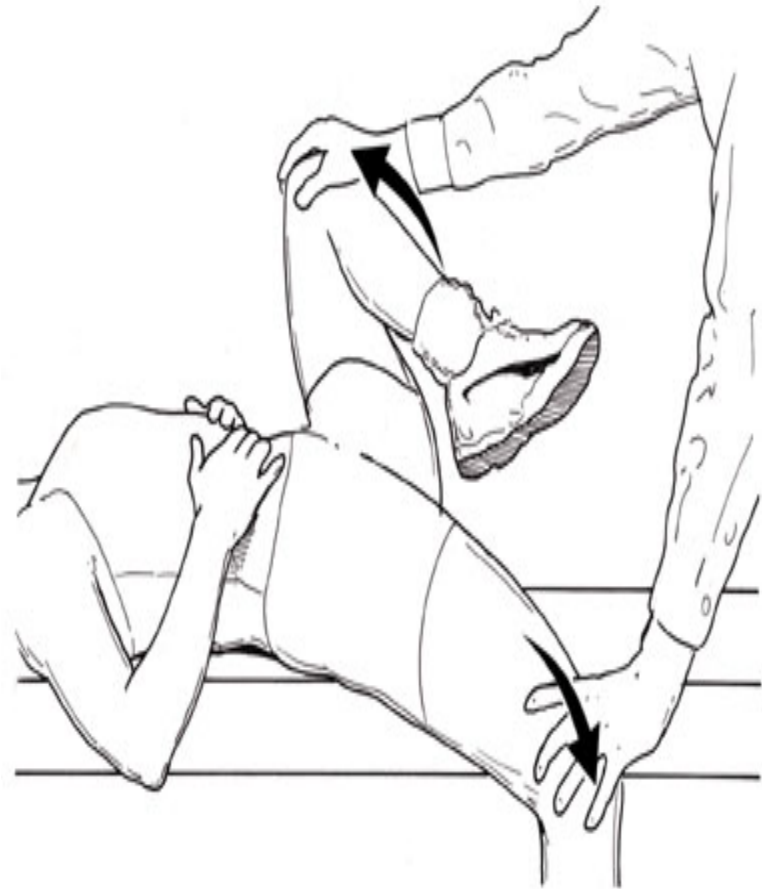- Subject supine, lying close to edge of table; examiner stands at side

- **Action:**

- Slide patient to edge of table; patient pulls far knee up to the chest; near leg allowed to hang over edge of table
- Examiner applies downward pressure on near leg, forcing it into hyperextension

- **Positive finding:**

- Pain in SI region indicating SI joint dysfunction





# Clinical Evaluation

- ***Long-Sitting Test:***

- **Test position:**

- Subject supine, both hips and knees extended; examiner standing with thumbs on subject's medial malleoli

- **Action:**

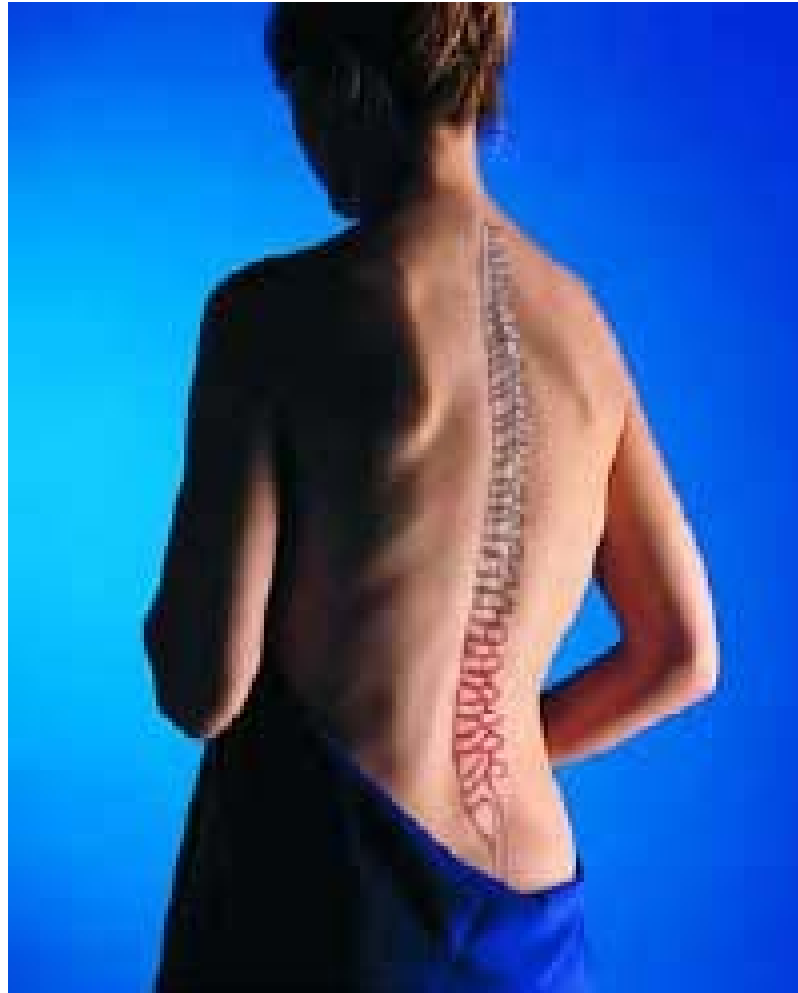- Examiner passively flexes both hips and knees and then fully extends and compares position of medial malleoli relative to each other
- Subject slowly assumes the long-sitting position and malleolar position is re-assessed

- **Positive finding:**

- Leg appears longer in supine but shorter in long-sitting is indicative of an ipsilateral anteriorly rotated ilium
- Leg appears shorter in supine but longer in long-sitting is indicative of an ipsilateral posteriorly rotated ilium

# Some tips

- get the patient to stand on their toes, thus checking plantar flexion of the foot and the S1 nerve root.
- If necessary, test each foot separately, giving them some support with an outstretched arm.
- Ask them to rock onto their heels - test of L4/L5



**hope that was useful to you**

Bone School @ Bangalore